

Periapical Bone Lesions and Radiographic Features

Periapikal Kemik Lezyonları ve Radyografik Özellikleri

Gaye Keser, Filiz Namdar Pekiner

Department of Oral and Maxillofacial Radiology, Marmara University School of Dentistry, İstanbul, Turkey

Cite this article as: Keser G, Namdar Pekiner F. Periapical Bone Lesions and Radiographic Features. Clin Exp Health Sci 2017; DOI: 10.5152/clinexphealthsci.2017.362

Abstract

Periapical bone lesions are frequently seen in dentistry and may lead to tooth loss when not treated. Dental radiographic imaging is an important tool for making an accurate diagnosis and for performing clinical examinations in endodontic treatment. Panoramic and periapical radiographic techniques provide adequate information, yet these techniques provide a two-dimensional representation of three-dimensional structures. Recently, cone-beam computed tomography (CBCT) systems have become available for the three-dimensional visualization of the craniofacial complex and periapical bone lesions, and the evaluation of periapical bone lesions with CBCT improves the prognosis of the current treatment pathology and prevents possible bone destruction. This article presents periapical bone lesions and radiographic features.

Keywords: Periapical lesion, radiology, panoramic radiography, cone beam computed tomography

Öz

Periapikal kemik lezyonları dişhekimliğinde sıklıkla görülmekte ve tedavi edilmediğinde diş kaybına neden olabilmektedir. Dental radyografik görüntüleme, endodonti alanında doğru bir tanı ve klinik muayene için önemli bir araçtır. Periapikal bölgede kemik yıkımının ilerlediği durumlarda periapikal lezyonlar intraroral radyografilerde rahatlıkla teşhis edilebilmesine karşın mevcut kemik yıkımlarının kemik korteksinde herhangi bir destrüksiyon ya da ekspansiyon yaratıp yaratmadığını iki boyutlu grafilerde değerlendirmek mümkün olmamaktadır. Son zamanlarda kraniyofasiyal kompleksin ve periapikal kemik lezyonlarının üç boyutlu olarak değerlendirilmesi için konik ışınlı bilgisayarlı tomografi (CBCT) sistemleri kullanılmaktadır. CBCT ile periapikal kemik lezyonlarının değerlendirilmesi mevcut patolojinin prognozunu ve olası kemik yıkımını önlemektedir. Bu makalede periapikal kemik lezyonları ve radyografik özellikleri sunulmuştur.

Anahtar Kelimeler: Periapikal lezyon, radyoloji, panoramik radyografi, konik ışınlı bilgisayarlı tomografi

INTRODUCTION

The diagnosis, localization, and evaluation of periapical bone lesions in dentistry are important during endodontic treatment. Periapical bone lesions are frequently seen in dentistry and may lead to tooth loss when not treated. An inflammatory result in periapical tissues occurs against agents that cause irritation due to a pulp tissue-originated inflammation. In the concerned region, bone destruction occurs following an acute or chronic process. The severity of the acute or chronic onset of inflammation in the periapical region resulting from bone destruction depends on the tissue resistance of the organism and intensity of the causative agent (1-3). As the penetration of X-rays is higher in the periapical inflammation area of bone destruction, more X-rays reach the periapical film; therefore, the radiogram appears radiolucent. This radiolucent area is separated from the surrounding tissue by the lamina dura or adjacent bone texture, resulting in the formation of a diffuse image (4-7).

Although periapical lesions can be easily identified on intraoral radiographs in cases where bone destruction progress in the periapical region, it is not possible to evaluate in the two-dimensional (2D) graphs whether the existing bone destruction creates any other destruction or expansion in the bone cortex from 2D graphs. In such cases, a three-dimensional (3D) imaging technique that removes the limitations of 2D radiographs should be used to accurately identify complex endodontic problems. In addition, this assessment improves the prognosis of the current treatment pathology and prevents possible bone destruction (8, 9).

Periapical lesions are complex multifactorial pathologies caused by necrotic pulp or failed canal therapy. Due to the fact that they are usually asymptomatic, the prognosis negatively affected. Epidemiological studies have shown that periapical lesions affect oral health in a large number of populations and that the incidence of periapical lesions is notably high (8-10).

CLINICAL AND RESEARCH CONSEQUENCES

The frequency of periapical lesions in studies conducted in the United States (39%), Lithuania (39%), Belgium (40%), Canada (44% and 51%), Kosovo (46.3%), Scotland (51%), Germany (61%), Spain (64.5%), and Turkey (67.9%) were found to be different (10-14).

Correspondence Author/ Sorumlu Yazar: Gaye Keser E-mail/E-posta: gayekeser@hotmail.com

Received/Geliş Tarihi: 13.02.2017 Accepted/Kabul Tarihi: 15.03.2017 Available Online Date/Çevrimiçi Yayın Tarihi: 17.07.2017 DOI: 10.5152/clinexphealthsci.2017.362

©Copyright by 2016 Journal of Marmara University Institute of Health Sciences - Available online at www.clinexphealthsci.com

©Telif Hakkı 2016 Marmara Üniversitesi Sağlık Bilimleri Enstitüsü - Makale metnine www.clinexphealthsci.com web sayfasından ulaşılabilir

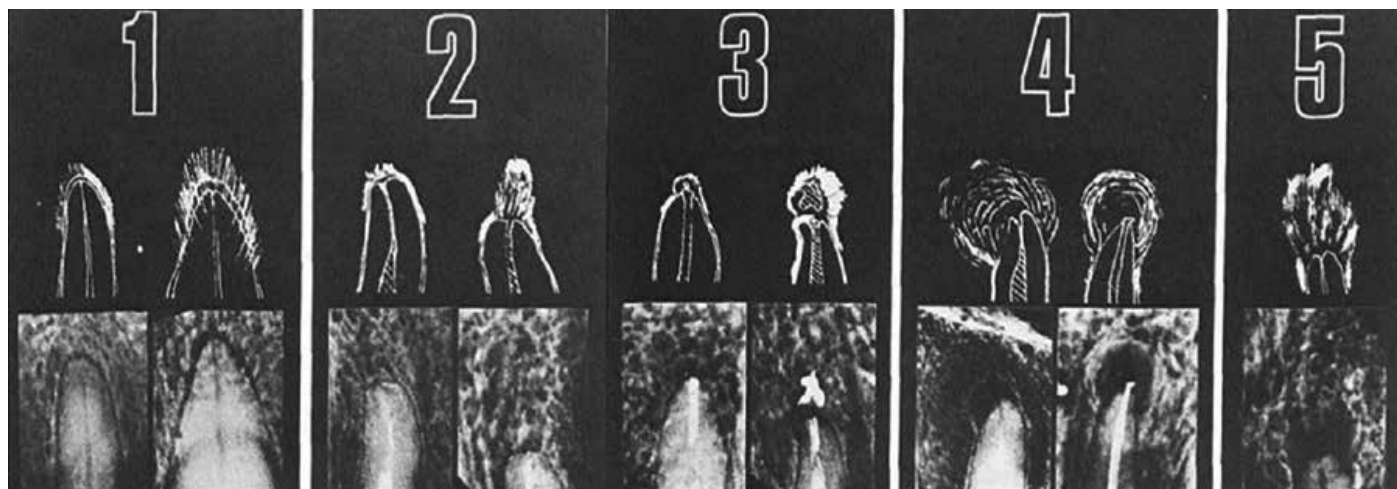


Figure 1. Periapical index scoring system [Ørstavik et al. (22)]

Table 1. Description of periapical index scores

Score	Description of radiographic findings
1	Normal periapical structures
2	Small changes in the bone structure
3	Change in the bone structure with mineral loss
4	Periodontitis with a well-defined radiolucent area
5	Severe periodontitis with exacerbating features

A number of cross-sectional and epidemiologic studies have been conducted to report the prevalence of periapical lesions with different radiographic techniques in various countries (15, 16).

Tsuneishi et al. (15) investigated the prevalence of periapical lesions and endodontic treatments in the Japanese society using periapical radiography. In the study, 87% of 672 patients had root canal treatment and 70% had periapical lesions. Moreover, root canal treatment was performed on 21% of 16232 teeth, and 40% of these teeth had periapical lesions. As a result, the prevalence of periapical lesions was found to be higher in teeth with root canal treatment.

In a study by Georgopoulou et al. (16), a total of 7378 teeth with root canal treatment and periapical lesions in 320 patients (age range, 16–77 years) in a Greek population were evaluated with periapical radiography by two observers. In the study, periapical lesions were observed in 1040 teeth (13.6%), and in 680 teeth (9.2%), root canal treatment was detected. Periapical lesions were detected in 408 teeth (60.0%) with root canal treatment. It was reported that the prevalence of periapical lesions was most frequent in molar teeth (23.9%), followed by premolar (14.0%) and anterior (9.4%) teeth.

In endodontic treatment, the diagnosis is based on a patient’s anamnesis, radiographs, and whether related teeth are vital. Furthermore, in some cases, radiography is not sufficient, and a histopathological evaluation is required (6, 17, 18).

Saraf et al. (6) evaluated periapical lesions in the images of 30 patients included in their study using intraoral radiography and a histopathological examination. A correlation between radiography and the histopathological examination was seen only in 30% of the patients, and

25% of the patients required the histopathological examination to confirm the results. Therefore, it is suggested that for confirmation of lesions, a histopathological examination accompanied by radiographic interpretation is required.

Several studies reporting successful root canal treatment have reported in the literature (17-20). Soikkonen et al. (19) evaluated images of 133 patients (45 males and 88 females, mean age: 76 years) using periapical radiography. Periapical lesions were detected in 16% of teeth with root canal treatment and in 4% of teeth with no treatment ($p < 0.0001$).

Tronstad et al. (20) evaluated coronal restoration in relation to the root canal filling and periapical status. The radiographic quality of root canal treatment was compared with the coronal restoration quality of endodontically treated teeth using 1001 periapical radiographs, and it was determined that periapical radiography was important in assessing the periapical condition.

One of the important factors affecting the success of root canal treatment and, thus, the formation of periapical lesions is the radiographic technique used. Peripheral radiography that is used in dentistry before, during, and after root canal treatment can reveal important findings such as root canal size, localization of the filling material, and pathologies around periapical tissues.

Hommez et al. (21) evaluated the quality of root canal treatment by performing periapical radiography of 745 teeth. The treatment quality and periapical status are categorized in terms of the presence or absence of periapical lesions. The study also examined the relationship between coronal restoration and the periapical status. Periapical lesions were detected in 33% of the 745 teeth. While periapical lesions were detected in 33.1% of the teeth with sufficient restoration, it was determined that this value was 36.8% in teeth with insufficiently applied crowns. Root canal posts were found to have no effect on the periapical status, but the length and homogeneity of the root canal filling was found to have a significant effect on periapical lesions.

Periodically obtaining radiographic images is important in the follow-up of root canal treatment. The periapical index (PAI) scoring system, which was introduced by Ørstavik et al. (22), who also applied PAI in clinical trials, demonstrates an ordinal scale of five scores

Table 2. Periapical index scoring system adapted for CBCT (CBCT-PAI)

Score	Periapical index adapted for CBCT (CBCT-PAI)
0	Intact periapical bone structures
1	Diameter of periapical radiolucency>0.5–1 mm
2	Diameter of periapical radiolucency>1–2 mm
3	Diameter of periapical radiolucency>2–4 mm
4	Diameter of periapical radiolucency>4–8 mm
5	Diameter of periapical radiolucency>8 mm
(n)+E	Expansion of the periapical cortical bone
(n)+D	Destruction of the periapical cortical bone

CBCT: cone-beam computed tomography; PAI: periapical index

ranging from no disease to severe periodontitis with exacerbating features (Figure 1, Table 1). Today this scoring system is commonly used in epidemiological studies in the literature (10, 23-25).

An important advantage of a scoring system such as PAI is that it has individual reproducibility and can be used to compare various investigations, Marques et al. (26) evaluated the panoramic radiographs of 179 subjects aged 30–39 years, and they found periapical lesions in 27% of the subjects. A total of 4446 teeth were evaluated, and the average number of teeth was 24.8 among the subjects. In addition, more than one periapical lesion (PAI score of 3–5) were found in 47 subjects (26%), and root canal treatment was performed once or more in 39 subjects (22%). It was also stated in that study that the PAI scoring system is useful for evaluating periapical lesions.

In a cross-sectional study by Archana et al. (27), 30098 teeth of 1340 patients were imaged by panoramic radiography and evaluated with the PAI scoring system. In the study, periapical lesions were detected in 462 (37.4%) of 1234 teeth with root canal treatment. It has also been reported that the 2D imaging technique yields less reliable results in the detection of periapical lesions than 3D imaging techniques. The study also revealed that that PAI scoring system provides a significant facility in terms of periapical lesion evaluation.

In another study in the literature, a total of 314 patient’s periapical radiographs were evaluated (28) using the PAI scoring system. In this study, 7694 teeth were evaluated, and it was detected that root canal treatment was performed on 412 teeth (5.3%). No periapical lesions were detected in 232 (56.3%) teeth with root canal treatment; in 180 (43.6%) teeth with root canal treatment, periapical lesions were observed.

Craveiro et al. (29) evaluated the relationship between the periapical status and the root canal treatment quality in a retrospective study. In the study, 523 teeth with root canal treatment in 337 patients (122 males and 215 females) were clinically and radiographically evaluated. The study group consisted of 83 patients (24.5%) between the ages of 18 and 30 ages and 161 patients (47.7%) between the ages of 31 and 50 years. Periapical radiography and the PAI scoring system were used for radiographic evaluation. The periapical status of 212 teeth (PAI 1+PAI 2) was found to be healthy, while periapical lesions were found in 311 teeth (PAI 3+PAI 4+PAI 5) in the study. The researchers concluded that with the help of the PAI scoring system, there is a correlation between the presence of periapical lesions and the success of root canal treatment.

Ridao-Sacie et al. (30) evaluated the periapical status using PAI by periapical and panoramic radiographic techniques in their study. In 86 patients (38 males and 48 females) between the ages of 30 and 79 years, a total of 2088 tooth images were evaluated, and it was determined that periapical radiography was more effective. However, it was reported that periapical radiographs were more difficult to evaluate in the maxillary second molar teeth and maxillary and mandibular third molar teeth ($p<0.01$).

2D radiographs have disadvantages in the detection of periapical lesions due to the superposition of anatomical points (31-33). Periapical lesions can be correctly detected with cone beam computed tomography (CBCT) by 3D multiplanar images as the superposition of anatomical points is eliminated with this imaging technique.

The CBCT-PAI scoring system was created by adding two variables, cortical bone expansion and destruction, to the existing PAI scoring system (Table 2). In a technical report published by Esposito et al. (32), a periapical radiograph and a CBCT image of a periapical lesion in a tooth with root canal treatment in a 52-year-old female were obtained. Periapical radiography evaluation was performed using PAI scoring. Immediately after, three separate sections (coronal, sagittal, and axial) obtained from the CBCT image were evaluated, and it was reported that buccal bone destruction was present. The authors of this technical report have stated that more reliable and sensitive data can be obtained in the detection of periapical lesions by 3D radiography.

Lemagner et al. (34) evaluated periapical lesions with CBCT imaging in their study. In the study, CBCT images (0.2×0.2×0.2 voxel) of 2368 teeth were examined, and periapical lesions were detected in 8.6% of the total teeth and 40.8% of the endodontically treated teeth. The most common periapical lesion diameter was 2–4 mm (39.2%) (CBCT-PAI score: 3). From this study, it was reported that CBCT imaging enables obtaining the most accurate data when periapical lesions are detected and evaluated in three dimensions.

In a study conducted by Fernandes et al. (35), 5585 teeth were assessed by CBCT. Ninety-two males and 124 females (mean age: 41.5±16.8 years) were included. In this study, the detection of periapical lesions was performed using CBCT and the CBCT-PAI scoring system. Periapical lesions were found in 110 patients (51.4%) and 192 teeth (3.4%). The incidence of periapical lesions was reported to be higher in patients in the 60–69-year age group than in the other age groups (73.1%). There was no statistical significance in the periapical lesion prevalence between males and females. In all three planes (coronal, sagittal, and axial), the largest diameter of the lesion was detected and the CBCT-PAI score was measured as 3. This study also reported that 76.2% of the patients did not have a cortical bone perforation.

Khetarpal et al. (36) evaluated the periapical lesion healing process using the CBCT-PAI scoring system. As a result of the clinical and radiographic examination of tooth number 21, a periapical lesion was detected in 3D cross-sectional images obtained using CBCT. When evaluation in the coronal, sagittal, and axial planes was performed, expansion and destruction of the cortical bone were observed and the pre-operative CBCT-PAI score was measured as 5+E+D. As a result of the study, it is stated that the CBCT-PAI scoring system provides more accurate data in the detection of periapical lesions.

Pope et al. (37) investigated periapical tissues using CBCT and periapical radiography. In the study, 200 teeth from 68 patients were evaluated using the CBCT-PAI and PAI scoring systems. CBCT-PAI scores measured were higher in 119 (72%) teeth than the PAI score. As a result, it was reported that the diversity seen in periapical tissues of the teeth can be visualized and evaluated in detail by CBCT.

CONCLUSION

The diagnosis of periapical bone lesions and the localization and assessment of the endodontic treatment plan are important in dentistry. An essential component of the management of endodontic problems is radiography. Traditional radiographic techniques such as panoramic radiography provide adequate information, yet these techniques provide a 2D representation of 3D structures. For several clinical and investigational purposes, CBCT has been used in endodontic treatment.

Peer-review: Externally peer-reviewed.

Author Contributions: Concept – G.K., F.N.P.; Design – G.K., F.N.P.; Supervision – F.N.P.; Resources – G.K., F.N.P.; Materials – G.K., F.N.P.; Data Collection and/or Processing – G.K., F.N.P.; Analysis and/or Interpretation – G.K., F.N.P.; Literature Search – G.K., F.N.P.; Writing Manuscript – G.K.; Critical Review – F.N.P.

Conflict of Interest: No conflict of interest was declared by the authors.

Financial Disclosure: This PhD thesis-based review was supported by Grant from Marmara University, Scientific Research Projects Committee (protocol number: SAG-C-DRP-100914-0315).

Hakem Değerlendirmesi: Dış bağımsız.

Yazar Katkıları: Fikir – G.K., F.N.P.; Tasarım – G.K., F.N.P.; Denetleme – F.N.P.; Kaynaklar – G.K., F.N.P.; Malzemeler – G.K., F.N.P.; Veri Toplanması ve/veya İşlemesi – G.K., F.N.P.; Analiz ve/veya Yorum – G.K., F.N.P.; Literatür Taraması – G.K., F.N.P.; Yazıyı Yazan – G.K.; Eleştirel İnceleme – F.N.P.

Çıkar Çatışması: Yazarlar çıkar çatışması bildirmemişlerdir.

Finansal Destek: Bu doktora tezi tabanlı inceleme, Marmara Üniversitesi'nden Grant, Bilimsel Araştırma Projeleri Komitesi (protokol numarası: SAG-C-DRP-100914-0315) tarafından desteklenmiştir.

REFERENCES

- Block RM, Bushell A, Rodrigues H, Langeland K. A histopathologic, histobacteriologic, and radiographic study of periapical endodontic surgical specimens. *Oral Surg Oral Med Oral Pathol* 1976; 42: 656-78. [\[Crossref\]](#)
- Rayner JA, Southam JC. Pulp changes in deciduous teeth associated with deep carious dentine. *J Dent* 1979; 7: 39-42. [\[Crossref\]](#)
- Figdor D. Apical periodontitis: A very prevalent problem. *Oral Surg Oral Med Oral Pathol* 2002; 94: 651-2. [\[Crossref\]](#)
- White SC, Pharoah MJ. *Oral Radiology; Principles and Interpretation*. 6 th ed. Missouri: Mosby Elsevier; 2009.p.2-329.
- Sogur E, Baksi BG, Grondahl HG, Sen BH. Pixel intensity and fractal dimension of periapical lesions visually indiscernible in radiographs. *J Endod* 2013; 39: 16-9. [\[Crossref\]](#)
- Saraf PA, Kamat S, Puranik RS, Puranik S, Saraf SP, Singh BP. Comparative evaluation of immunohistochemistry, histopathology and conventional radiography in differentiating periapical lesions. *J Conserv Dent* 2014; 17: 164-8. [\[Crossref\]](#)
- Venskutonis T, Daugela P, Strazdas M, Juodzbalsys G. Accuracy of Digital Radiography and Cone Beam Computed Tomography on Periapical Radiolucency Detection in Endodontically Treated Teeth. *J Oral Maxillofac Res* 2014; 5: e1. [\[Crossref\]](#)
- Patel S, Dawood A, Ford TP, Whaites E. The potential applications of cone beam computed tomography in the management of endodontic problems. *Int Endod J* 2007; 40: 818-30. [\[Crossref\]](#)
- Jorge ÉG, Tanomaru-Filho M, Guerreiro-Tanomaru JM, Reis JM, Spin-Neto R, Gonçalves M. Periapical repair following endodontic surgery: two- and three-dimensional imaging evaluation methods. *Braz Dent J* 2015; 26: 69-74. [\[Crossref\]](#)
- Eriksen HM, Bjertness E, Ørstavik D. Prevalence and quality of endodontic treatment in an urban adult population in Norway. *Endod Dent Traumatol* 1988; 2: 122-6. [\[Crossref\]](#)
- Weiger R, Hitzler S, Hermlé G, Löst C. Periapical status, quality of root canal fillings and estimated endodontic treatment needs in an urban German population. *Endod Dent Traumatol* 1997; 13: 69-74. [\[Crossref\]](#)
- De Moor RJ, Hommez GM, De Boever JG, Delme KI, Martens GE. Periapical health related to the quality of root canal treatment in a Belgian population. *Int Endod J* 2000; 33: 113-20. [\[Crossref\]](#)
- Segura-Egea JJ, Castellanos-Cosano L, Machuca G, Lopez-Lopez J, Martin-Gonzalez J, Velasco-Ortega E, et al. Diabetes mellitus, periapical inflammation and endodontic treatment outcome. *Med Oral Patol Oral Cir Bucal* 2012; 17: e356-61. [\[Crossref\]](#)
- Berlinck T, Tinoco JM, Carvalho FL, Sassone LM, Tinoco EM. Epidemiological evaluation of apical periodontitis prevalence in an urban Brazilian population. *Braz Oral Res* 2015; 29: 1-7. [\[Crossref\]](#)
- Tsuneishi M, Yamamoto T, Yamanaka R, Tamaki N, Sakamoto T, Tsuji K, et al. Radiographic evaluation of periapical status and prevalence of endodontic treatment in an adult Japanese population. *Oral Surg Oral Med Oral Pathol Oral Radiol Endod* 2005; 100: 631-5. [\[Crossref\]](#)
- Georgopoulou MK, Spanaki-Voreadi AP, Pantazis N, Kontakiotis EG. Frequency and distribution of root filled teeth and apical periodontitis in a Greek population. *Int Endod J* 2005; 38: 105-11. [\[Crossref\]](#)
- Maity I, Kumari A, Shukla AK, Usha H, Naveen D. Monitoring of healing by ultrasound with colour power Doppler after root canal treatment of maxillary anterior teeth with periapical lesions. *J Conserv Dent* 2011; 14: 252-7. [\[Crossref\]](#)
- Abbott PA. Endodontics-Current and future. *J Conserv Dent* 2012; 15: 202-5. [\[Crossref\]](#)
- Soikkonen KT. Endodontically treated teeth and periapical findings in the elderly. *Int Endod J* 1995; 28: 200-3. [\[Crossref\]](#)
- Tronstad L, Asbjørnsen K, Døving L, Pedersen I, Eriksen HM. Influence of coronal restorations on the periapical health of endodontically treated teeth. *Endod Dent Traumatol* 2000; 16: 218-21. [\[Crossref\]](#)
- Hommez GMG, Coppens CRM, De Moor RJG. Periapical health related to the quality of coronal restorations and root fillings. *Int Endod J* 2002; 35: 680-9. [\[Crossref\]](#)
- Ørstavik D, Kerekes K, Eriksen HM. The periapical index: a scoring system for radiographic assessment of apical periodontitis. *Endod Dent Traumatol* 1986; 2: 20-4. [\[Crossref\]](#)
- Sidaravicius B, Aleksejuniene J, Eriksen HM. Endodontic treatment and prevalence of apical periodontitis in an adult population of Vilnius, Lithuania. *Endod Dent Traumatol* 1999; 6: 210-5. [\[Crossref\]](#)
- Lupi-Pegurier L, Bertrand MF, Muller-Bolla M, Rocca JP, Bolla M. Periapical status, prevalence and quality of endodontic treatment in an adult French population. *Int Endod J* 2002; 35: 690-7. [\[Crossref\]](#)
- Dugas NN, Lawrence HP, Teplitsky PE, Pharoah MJ, Friedman S. Periapical health and treatment quality assessment of root-filled teeth in two Canadian population. *Int Endod J* 2003; 36: 181-92. [\[Crossref\]](#)
- Marques MD, Moreira B, Eriksen HM. Prevalence of apical periodontitis and results of endodontic treatment in an adult, Portuguese population. *Int Endod J* 1998; 31: 161-5. [\[Crossref\]](#)
- Archana D, Gopikrishna V, Gutmann JL, Savadamoorthi KS, Kumar AP, Narayanan LL. Prevalence of periradicular radiolucencies and its associa-

- tion with the quality of root canal procedures and coronal restorations in an adult urban Indian population. *J Conserv Dent* 2015; 18: 34-8. [\[Crossref\]](#)
28. Yılmaz Z, Görduysus Ö. Endodontik tedavilerin kalitesi ile periapikal durum arasındaki ilişkinin periapikal indeks skorum (PAI) yöntemi ile değerlendirilmesi. *Hacettepe Dişhekimliği Fakültesi Dergisi* 2007; 31: 96-104.
 29. Craveiro MA, Fontana CE, de Martin AS, Bueno CE. Influence of Coronal Restoration and Root Canal Filling Quality on Periapical Status: Clinical and Radiographic Evaluation. *J Endod* 2015; 41: 836-40. [\[Crossref\]](#)
 30. Rıdao-Sacie C, Segura-Egea JJ, Fernández-Palacín A, Bullón-Fernández P, Ríos-Santos JV. Radiological assessment of periapical status using the periapical index (PAI): comparison of periapical radiography and digital panoramic radiography. *Int Endod J* 2007; 40: 433-40. [\[Crossref\]](#)
 31. Estrela C, Bueno MR, Azevedo BC, Azevedo JR, Pecora JD. A new periapical index based on cone beam computed tomography. *J Endod* 2008; 34: 1325-31. [\[Crossref\]](#)
 32. Esposito S, Cardaropoli M, Cotti E. A suggested technique for the application of the cone beam computed tomography periapical index. *Dentomaxillofac Radiol* 2011; 40: 506-12. [\[Crossref\]](#)
 33. Nur BG, Ok E, Altunsoy M, Ađlarci OS, olak M, Gngr E. Evaluation of technical quality and periapical health of root-filled teeth by using cone-beam CT. *J Appl Oral Sci* 2014; 22: 502-8. [\[Crossref\]](#)
 34. Lemagner F, Maret D, Peters OA, Arias A, Coudrais E, Georgelin-Gurgel M. Prevalence of Apical Bone Defects and Evaluation of Associated Factors Detected with Cone-beam Computed Tomographic Images. *J Endod* 2015; 41: 1043-7. [\[Crossref\]](#)
 35. Fernandes LMPSR, Ordinola-Zapata R, Hngaro Duarte MA, Alvares Capelozza AL. Prevalence of apical periodontitis detected in cone beam CT images of a Brazilian subpopulation. *Dentomaxillofac Radiol* 2013; 42: 80179163. [\[Crossref\]](#)
 36. Khetarpal A, Chaudhary S, Sahai S, Talwar S, Verma M. Radiological assessment of periapical healing using the cone beam computed tomography periapical index: case report. *IOSR-JDMS* 2013; 5: 46-51. [\[Crossref\]](#)
 37. Pope O, Sathorn C, Parashos P. A Comparative Investigation of Cone-beam Computed Tomography and Periapical Radiography in the Diagnosis of a Healthy Periapex. *J Endod* 2014; 40: 360-5. [\[Crossref\]](#)