

# Riboflavin Treatment Reduces Apoptosis and Oxidative DNA Damage in a Rat Spinal Cord Injury Model

## Omurilik Hasarı Oluşturulan Sıçan Modelinde Riboflavin Tedavisi Apoptozu ve Oksidan DNA Hasarını Azaltır

Sinem Sakarcan<sup>1</sup>, Mehmet Erşahin<sup>2</sup>, Mehmet Emin Eminoğlu<sup>2</sup>, Özge Çevik<sup>3</sup>, Esin Ak<sup>4</sup>, Feriha Ercan<sup>5</sup>, Göksel Şener<sup>6</sup>

<sup>1</sup>Department of Medical Sciences, The Commonwealth Medical College, Scranton, Pennsylvania, USA

<sup>2</sup>Department of Neurosurgery, Medeniyet University School of Medicine, İstanbul, Turkey

<sup>3</sup>Department of Biochemistry, Cumhuriyet University School of Pharmacy, Sivas, Turkey

<sup>4</sup>Department of Basic Medical Sciences, Marmara University School of Medicine, İstanbul, Turkey

<sup>5</sup>Department of Histology/Embryology, Marmara University School of Medicine, İstanbul, Turkey

<sup>6</sup>Department of Pharmacology, Marmara University School of Pharmacy, İstanbul, Turkey

### Abstract

**Objective:** Spinal cord injury (SCI) leads to an inflammatory response and results in oxidative stress, which has deleterious effects on several organ systems. Riboflavin is an easily absorbed micronutrient that plays an important role in maintaining health in humans and animals. The present study was designed to investigate the putative protective effect of riboflavin against SCI-induced spinal cord and kidney damage.

**Methods:** In order to induce SCI, the standard weight-drop method was used to induce a moderately severe injury (100 g/cm force) at the T10 vertebral level. Injured animals were given either 25 mg/kg riboflavin or carboxymethyl cellulose 15 min after injury, and this regimen was repeated twice daily for 7 days. On the 7<sup>th</sup> post-injury day, a neurological examination was performed and rats were sacrificed. Spinal cord and kidney samples were harvested and prepared for a histological examination. Tissue levels of malondialdehyde (MDA), glutathione (GSH), and 8-hydroxy-2'-deoxyguanosine (8-OHdG) and activities of myeloperoxidase (MPO), superoxide dismutase (SOD), and caspase-3 were determined.

**Results:** SCI caused a significant decrease in tissue GSH levels and SOD activities, which were accompanied by significant increases in MDA and 8-OHdG levels and MPO and caspase-3 activities. However, riboflavin treatment reversed these parameters and improved histological findings.

**Conclusion:** SCI caused tissue injury through oxidative stress and neutrophil infiltration into tissues. Riboflavin inhibited tissue injury through its neuroprotective and antiapoptotic effects. Moreover, our study demonstrated that riboflavin not only exerts antioxidant and antiapoptotic effects on the spinal cord but also has a significant impact on preventing kidney damage secondary to SCI.

**Keywords:** Spinal cord injury, riboflavin, oxidative damage

### Öz

**Amaç:** Omurilik hasarı inflamatuvar yanıtta ve oksidatif strese yol açarak çeşitli organ sistemlerinde zararlı etkiler oluşturur. Riboflavin insan ve hayvanda sağlığın sürdürülmesinde önemli role sahip olan ve kolayca absorbe edilen mikrobeseindir. Bu çalışma omurilik yaralanmasına bağlı omurilik ve böbrek dokusunda riboflavinin koruyucu etkilerini araştırmak üzere planlandı.

**Yöntemler:** Omurilik hasarı oluşturmak için anestezi altındaki sıçanlara T10 seviyesinde 100 g/cm şiddetinde ağırlık düşürme metodu uygulandı. Hasarlı hayvanlara riboflavin 25 mg/kg dozunda ya da taşıyıcı çözelti tedavisi hasardan 15 dakika sonra verildi ve 7 gün süreyle devam edildi. Hasardan sonra 7.günde nörolojik testin arkasından hayvanlar dekapite edilerek spinal ve böbrek dokuları alındı. Dokularda histolojik tayinler yapıldı ve malondialdehit (MDA), glutatyon (GSH), 8-hidroksi-2'-deoksiguanozin (8-OHdG) düzeyleri ile myeloperoksidaz (MPO), süperoksit dismutaz (SOD) ve katalaz aktiviteleri tayin edildi.

**Bulgular:** Omurilik hasarı dokularda GSH düzeylerinde ve SOD aktivitesinde azalmaya, MDA düzeyinde ve MPO ve kaspaz aktivitelerinde artışa neden oldu. Riboflavin tedavisi bu parametreleri geri çevirdi ve histolojik bulgularda düzelmeye gösterdi.

**Sonuç:** Çalışmamızda Omurilik hasarı, dokuya nötrofil göçüne ve oksidan strese yol açarken, antiapoptotik ve nöroprotektif özellikleri ile riboflavin lipid peroksidasyonunu ve nötrofillerin dokuya infiltrasyonunu inhibe etti. Ayrıca, çalışmamız riboflavinin antiapoptotik ve antioksidan etkisinin sadece omurilikte değil omurilik hasarında ikincil olarak ortaya çıkan böbrek hasarında da önemli faydaları olduğunu gösterdi.

**Anahtar kelimeler:** Omurilik hasarı, riboflavin, oksidan hasar

### INTRODUCTION

Spinal cord injury (SCI) mostly occurs due to trauma but may also occur iatrogenically or due to infection, tumors, or vascular lesions (1). Trauma to the spinal cord causes the loss or degradation of motor, sensory, and autonomic functions and requires lifelong treatment, which affects not only patients but also their families (2). An understanding of the pathogenesis of SCI could provide an effective treatment solution. However, to date, there have been no treatment protocols that have provided both neurological and functional recovery.

SCI can be divided into primary and secondary injuries. Primary injury is mechanical and related to focal neural damage that is amenable to neuroprotective therapies (3). Secondary injury is exaggerated through the activation of systemic immunity at the site of a lesion and the inflammatory reaction by immune cell infiltration. Secondary mechanisms of injury include oxidative stress, inflammation, changes in ion influx, and increases in release of excitatory amino acids and cellular apoptosis. All these mechanisms can be targeted for treatment (4-6). The agents used in this study have not only anti-inflammatory and antioxidant effects but also the capability to hasten the recovery of damaged tissues (7).

Riboflavin, also known as vitamin B2, is an important micronutrient that plays a key role in maintaining health in humans and animals. It is a precursor of flavin mononucleotide (FMN) and flavin adenine dinucleotide (FAD), which act as electron carriers, and therefore, plays an important role in a range of redox reactions, mitochondrial energy production, and cellular function (8, 9). It has been reported that riboflavin protects cells against the harmful effects of reactive oxygen metabolites that can cause damage to lipids, proteins, and DNA, subsequently leading to cell stress and an increase in apoptosis (10, 11). Yu et al. (12) demonstrated that riboflavin has an antioxidant effect through superoxide dismutase (SOD) activation. Furthermore, riboflavin showed anti-inflammatory effects in various experimental models such as carrageenan-induced paw edema, lipopolysaccharide-induced fever, and implantation of cotton pellet-induced fibrovascular tissues (13, 14).

Based on the above findings, we investigated the putative protective effect of riboflavin against SCI-induced oxidative tissue damage in the spinal cord and kidney using biochemical and histopathological approaches.

## METHODS

### Animals and Experimental Design

Wistar albino rats (250-300 g) supplied by the Marmara University (MU) Application and Research Center for Experimental Animals were housed in an air-conditioned room with 12:12 h light:dark cycles. The temperature ( $22\pm 2^\circ\text{C}$ ) and relative humidity (65–70%) were kept constant. All experimental protocols were approved by the MU Animal Care and Use Committee.

Rats were randomly divided into three groups (8 rats in each): Group 1, control group (C): rats underwent sham surgery and received the oral vehicle only [carboxymethyl cellulose (CMC)], Group 2, rats underwent surgery for SCI induction and received the oral vehicle only (SCI group). Group 3, SCI group: rats underwent surgery for SCI induction and received riboflavin (25 mg/kg/day orally) (SCI+Ribo group). Treatments were started 15 min after injury and continued for the following 7 days. Riboflavin was dissolved in 0.5% CMC.

To prevent urinary retention, SCI rats received manual bladder expression twice a day by restraining the rat in one hand and gently expressing the bladder with the fingertips of the other hand. Neurological examinations were performed one week after the sham surgery or SCI induction, and rats were then sacrificed in order to obtain spinal cord and kidney samples for biochemical and histological analyses.

### Induction of SCI

Rats were anesthetized and placed on a thermostat-controlled heating pad in the prone position with a rectal probe inserted. Under sterile conditions, a skin incision was made and paravertebral muscle dissection was performed following the T5-T12 midline and spinous processes; then, the laminar arcs were removed from T7-10. SCI was induced using the modified weight-drop model (15). The dorsal surface of the spinal cord of rats was subjected to an impact of 100 g/cm (10 g weight from a 10 cm height). The weight was composed of a stainless steel rod (3-mm diameter tip) that was rounded at the surface. A 10-cm guide tube, positioned perpendicular to the center of the spinal cord, was used to drop the rod vertically onto the spinal cord. After the incision was sutured, rats were placed in a warming chamber to maintain their body temperature at approximately  $37^\circ\text{C}$  until they were completely awake.

### Neurological Examination

Motor function scores of Gale et al. (16) were used to perform the neurological examination. A "blinded" investigator, who was unaware of the treatment conditions, conducted all behavioral tests. The testing of rats was randomly done for a given task.

### Biochemical Assays on Spinal Cord and Kidney Tissues:

#### Measurement of Tissue Myeloperoxidase (MPO) Activity

Spinal cord and kidney tissue myeloperoxidase activity was measured by a procedure similar to that performed by Hillegas et al. (17). Homogenization of tissue samples was performed in a 50 mM potassium phosphate buffer (PB) with a pH of 6.0; samples centrifuged at 41,400 g for 10 min. Next, pellets were suspended in a solution of 50 mM PB containing 0.5% hexadecyltrimethylammonium bromide. Samples were centrifuged at 41,400 g for 10 min after three freeze-thaw cycles, with sonication between cycles. Aliquots (0.3 mL) were added to 2.3 mL of a reaction mixture containing 50 mM PB, o-dianisidine, and 20 mM  $\text{H}_2\text{O}_2$  solution. One unit of enzyme activity was defined as the amount of MPO present that caused a change in absorbance, measured at 460 nm, for 3 min.

#### Measurement of Tissue Malondialdehyde (MDA) and Glutathione (GSH) Levels

MDA and GSH levels were determined by homogenization of spinal cord and kidney tissue samples in ice-cold 150 mM KCl. Thiobarbituric acid-reactive substances were monitored to check for products of lipid peroxides in order to determine MDA levels (18). Lipid peroxidation was expressed in terms of MDA equivalents using an extinction coefficient of  $1.56\times 10^5\text{ M}^{-1}\text{ cm}^{-1}$ . A modified version of the Ellman procedure was performed to measure GSH levels (19). First, a sample was centrifuged at 2000 g for 10 min, and then, 0.5 mL of the supernatant was added to 2 mL of 0.3 mol/l  $\text{Na}_2\text{HPO}_4$  solution. Next, a 0.2 mL solution of dithiobisnitrobenzoate (0.4 mg/mL of 1% sodium citrate) was added to the previous mixture. Immediately after mixing, the absorbance was measured at 412 nm. The GSH levels were then calculated using an extinction coefficient of  $1.36\times 10^4\text{ M}^{-1}\text{ cm}^{-1}$ .

#### Measurement of Tissue 8-hydroxy-2'-deoxyguanosine (8-OHdG) Levels

After tissue samples were collected, genomic DNA from the tissues was immediately extracted using a commercial DNA extraction kit according to the manufacturer's protocol. Next, the samples were stored at  $-80^\circ\text{C}$  for the measurement of 8-OHdG levels. The tissue lev-

els of 8-OHdG were measured by competitive ELISA using an OxiSelect™ Oxidative DNA Damage ELISA kit according to the manufacturer's instructions (Cell Biolabs, US).

**Measurement of Superoxide Dismutase (SOD) Activity**

Tissue sample SOD activity was measured according to the method previously described by Mylroie et al. (20) Bovine SOD (Sigma Chemical Co., Saint Louis, USA; S-2515, 3000 U) was used to prepare a standard reference curve. Absorbance measurements were read at 0 and 8 min of illumination, and the net absorbance was calculated.

**Western Blot Analysis for Caspase-3 Protein Expression**

The previously described Western blot procedure was used to measure caspase-3 release (21). The Bradford method was used to determine protein concentrations in homogenized samples (22). After 25 µg of the protein was resolved on 12% SDS-PAGE, it was then transferred to a nitrocellulose membrane (sc-3718, Santa Cruz Biotechnology). The nitrocellulose membrane was blocked using 5% nonfat skim milk powder (Sigma, 70166) in Tris-buffered saline (TBS) and washed twice in TBS containing 0.1% Tween-20 followed by incubation overnight with a primary antibody (1:1000 goat anti-mouse IgG1-HRP, sc-2060, Santa Cruz Biotechnology) for 2 h. The blot was established with reagents, and data were analyzed using the Image J Program OD analysis software. Signals were normalized with respect to β-actin.

**Histological Analysis**

For a light microscopic examination, the spinal cord and kidney tissue samples were fixed with 10% neutral formalin, dehydrated in an ascending alcohol series, cleared with toluene, and embedded in paraffin. Approximately 5-µm thick spinal cord sections were stained with cresyl violet, and kidney sections were stained with hematoxylin and eosin. Stained sections were evaluated with an Olympus BX51 photomicroscope (Tokyo, Japan) and photographed with an Olympus DP72 digital camera (Tokyo, Japan).

**Statistical Analysis**

GraphPad Prism 5.0 (GraphPad Software, San Diego; CA; USA) was used to perform statistical analyses. All data were expressed as means±SEM. Analysis of variance was used to compare groups of data followed by Tukey's multiple comparison tests. The Mann-Whitney U test was used to evaluate neurological examination scores. Values of p<0.05 were considered significant.

**RESULTS**

**Motor Function Score**

The average score for the neurological examination recorded on the 7<sup>th</sup> day of SCI induction was significantly lower in the vehicle-treated SCI group (p<0.001) compared to that of the sham-operated control group. SCI-induced rats treated with riboflavin had partially reversed neurological impairment (p<0.05), although not as good as the control score (Figure 1).

**Biochemical Parameters**

When compared with the control group, SCI caused a significant increase (p<0.01-0.001) in both spinal cord and kidney tissue MPO activities as an index of tissue neutrophil infiltration (Figure 2). In the SCI-induced rats that received riboflavin treatment, the elevations in MPO activities were abolished (p<0.01).

The MDA levels in the spinal cord and kidney tissues were significantly higher in the SCI group than in the control group (p<0.001, Figure 3a, b) while treatment with riboflavin significantly reduced

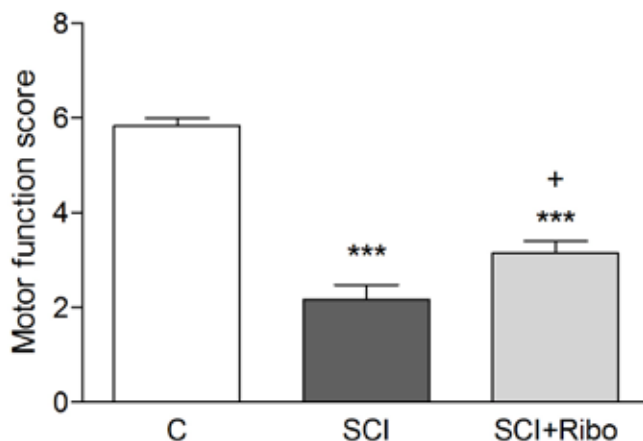


Figure 1. Neurological examination scores of rats in the control (C), SCI (Group 2) and SCI+Ribo (Group 3) groups. Each group consisted of eight rats. Values are represented as mean±SEM. \*\*\*p<0.001 vs control group; +p<0.05, vs SCI group

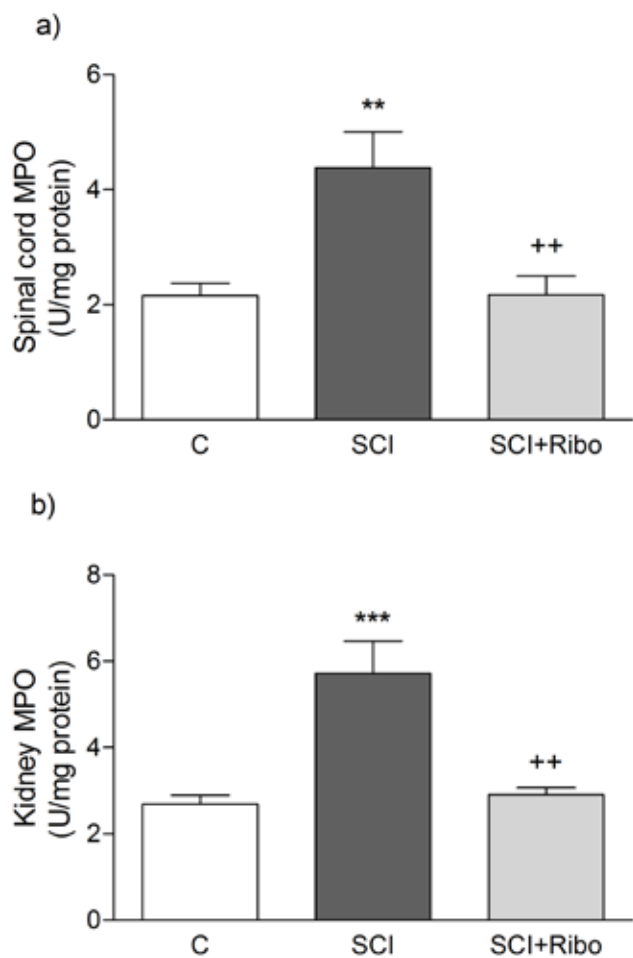


Figure 2. a, b. MPO activity in (a) spinal cord and (b) kidney tissues of rats in the C, SCI, and SCI+Ribo groups. Each group consisted of eight rats. Values are represented as mean±SEM. \*\*p<0.01, \*\*\*p<0.001 vs C group; ++p<0.01, vs SCI group

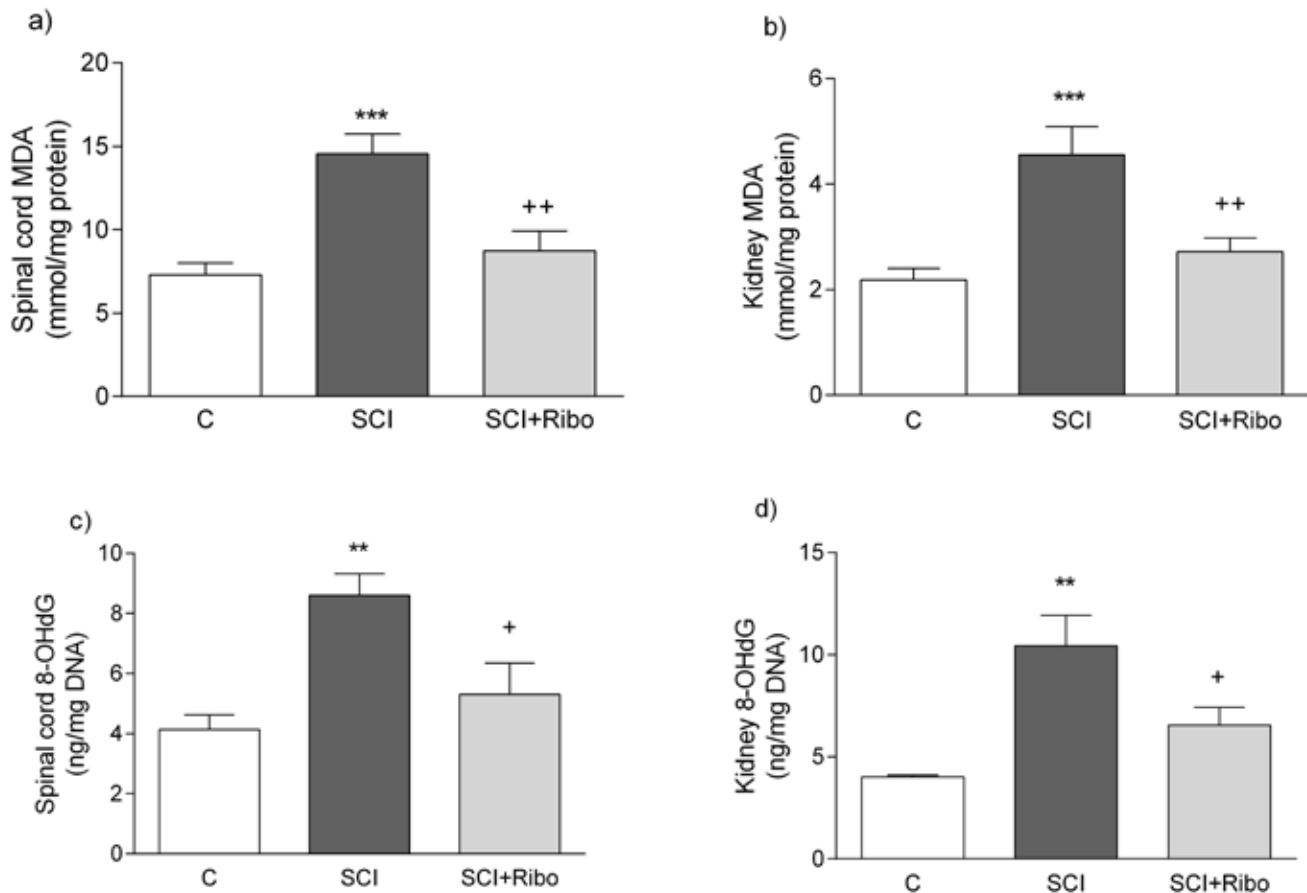


Figure 3. a-d. MDA levels in (a) spinal cord and (b) kidney tissues and 8-OHdG levels in (c) spinal cord and (d) kidney tissues of rats in the C, SCI, and SCI+Ribo groups. Each group consisted of eight rats. Values are represented as mean±SEM \*\*p<0.01, \*\*\*p<0.001 vs C group; +p<0.05, ++p<0.01 vs SCI group

the MDA levels in both tissues ( $p<0.01$ ) to achieve values close to the control levels.

8-OHdG levels, which are an accepted indicator for oxidative DNA damage, were found to be significantly increased in the spinal cord and kidney tissues of SCI rats ( $p<0.01$ , Figure 3c, d). On the other hand, riboflavin treatment in the SCI group significantly reversed these increases ( $p<0.05$ ).

As shown in Figure 4, SCI caused significant ( $p<0.05-0.001$ ) depletion of tissue GSH levels (Figure 4a, b) and reduction in SOD activities (Figure 4c, d) in both tissues. Furthermore SCI-induced changes in antioxidants were found to be reversed in riboflavin treated SCI rats.

Semi-quantitative Western blot analysis indicated an increase in caspase-3 protein expressions in both spinal cord (Figure 5) and kidney (Figure 6) tissues of SCI damaged rats ( $p<0.001$ ). On the other hand, the SCI-mediated rise in apoptosis was significantly depressed after treatment with riboflavin ( $p<0.01-0.001$ ).

### Histological Results

Light microscopy observation of the spinal cord in control rats showed regular white and gray matter with neuropil and neurons (Figure 7a). Group 2 showed degenerated white and gray matter. Neuropil architecture was disrupted, vacuole formation, perivascular and perineural edema, and degenerated neurons were observed in

this group (Figure 7b). On the other hand, Group 3 showed decreased degeneration of both white and gray matter with less vacuole formation and neuronal damage (Figure 7c).

Light microscopy observation of kidney tissues in control rats showed regular renal parenchyma with glomeruli and tubuli (Figure 7d). Group 2 (Figure 7e) showed degenerated renal corpuscles with dilated Bowman space and atrophic glomeruli, degenerated tubular cells, luminal debris, and severe vascular congestion in the renal parenchyma. Furthermore, Group 3 (Figure 7f) showed reduced degeneration in renal parenchyma with moderate glomerular and tubular degeneration and mild vascular congestion.

### DISCUSSION

The current study demonstrated that SCI induces inflammatory and oxidative injury in both spinal cord and kidney tissues because MPO activity, caspase-3 protein expression, MDA levels, and 8-OHdG levels were elevated. Moreover, tissue antioxidants, such as GSH and SOD, were depleted due to increased oxidative injury. The present findings clearly show that riboflavin treatment in SCI-damaged rats reverses these changes and protects against SCI-induced tissue damage.

Since the secondary damage of SCI is involved in various pathways, choosing a treatment strategy that targets a specific path is not believed to result in successful outcomes. Riboflavin has been well

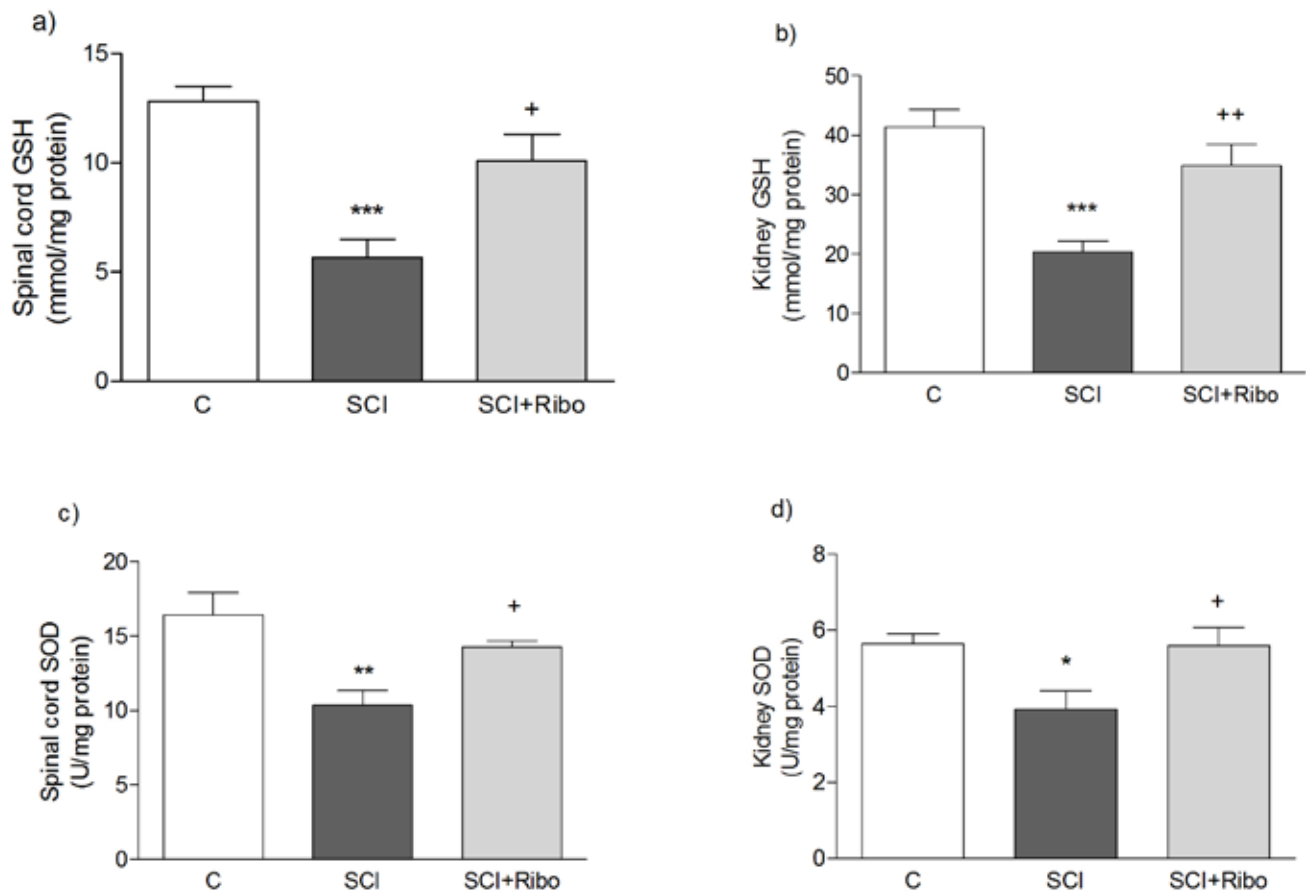


Figure 4. a-d. GSH levels in (a) spinal cord and (b) kidney tissues and SOD activity in (c) spinal cord and (d) kidney tissues of rats in the C, SCI, and SCI+Ribo groups. Each group consisted of eight rats. Values are represented as mean±SEM \* $p<0.05$ , \*\* $p<0.01$ , \*\*\* $p<0.001$  vs C group; + $p<0.05$ , ++ $p<0.01$  vs SCI group

known to participate in a variety of redox reactions vital to human metabolism through cofactors such as FMN and FAD, which act as electron carriers (23).

FAD is used as a cofactor for most flavoproteins. Riboflavin deficiency would be expected cause disturbances in certain steps of metabolism. It can be relatively difficult to trace the physiological and clinical implications of riboflavin deficiency to specific metabolic steps.

Although studies in humans are limited, previous studies have shown neurological complications due to riboflavin deficiency and an improvement with riboflavin supplementation (8, 24). Our study supports this by showing that riboflavin treatment for SCI-induced motor dysfunction was partially reversed. Although the motor function of the riboflavin-treated SCI rats did not reach the values of the control group, they showed signs of improvement compared to the untreated SCI rats. Mitochondria play an important role in cellular bioenergetics, function, and survival, and this indicates that mitochondrial functions need to be taken into consideration when choosing treatment approaches (25). Similarly, Mishra and Kumar, who studied the protective effects of caffeine on motor dysfunction induced by quinolinic acid, showed that mitochondrial NAD(+)/FAD(+)-linked state-3 respiration plays a role in this mechanism (26). Based on the findings of Mishra and Kumar, it is hypothesized that riboflavin, in this present study, has an augmentative effect in motor

functions through the previously stated pathway. The reason for this is because riboflavin is a precursor to FMN and FAD, and riboflavin is required for mitochondrial energy production as well as the completion of redox reactions.

SCI is an irreversible pathologic phenomenon that leads to the circulation of inflammatory cells, resulting in systemic inflammation and multi-organ failure and dysfunction that can have enormous tragic implications on the patient and the family. In our previous studies with SCI-induced bladder and erectile dysfunction, we demonstrated that the damage was due inflammatory and oxidative stress mechanisms (21, 27). Similarly, the results of this study also showed that SCI-induced multi-organ damage is the result of inflammation and free radicals.

Because renal tissue is highly dependent on oxygen, it becomes very sensitive to oxidative injury leading to renal failure, which causes an increase in mortality and morbidity. The kidney tissue analyzed in our study showed an increase in MPO activity, an indicator of inflammation and neutrophil infiltration to the tissues. Neutrophil infiltration and increased MPO activity, producing HOCl, deactivates antiproteases and activates latent proteases. This ultimately leads to an increase in oxidant-induced tissue injury (28). Heinzelmann et al. (29) suggested that chemotactic substances released by mesangial cells and neutrophils augment neutrophil migration to the kidney,

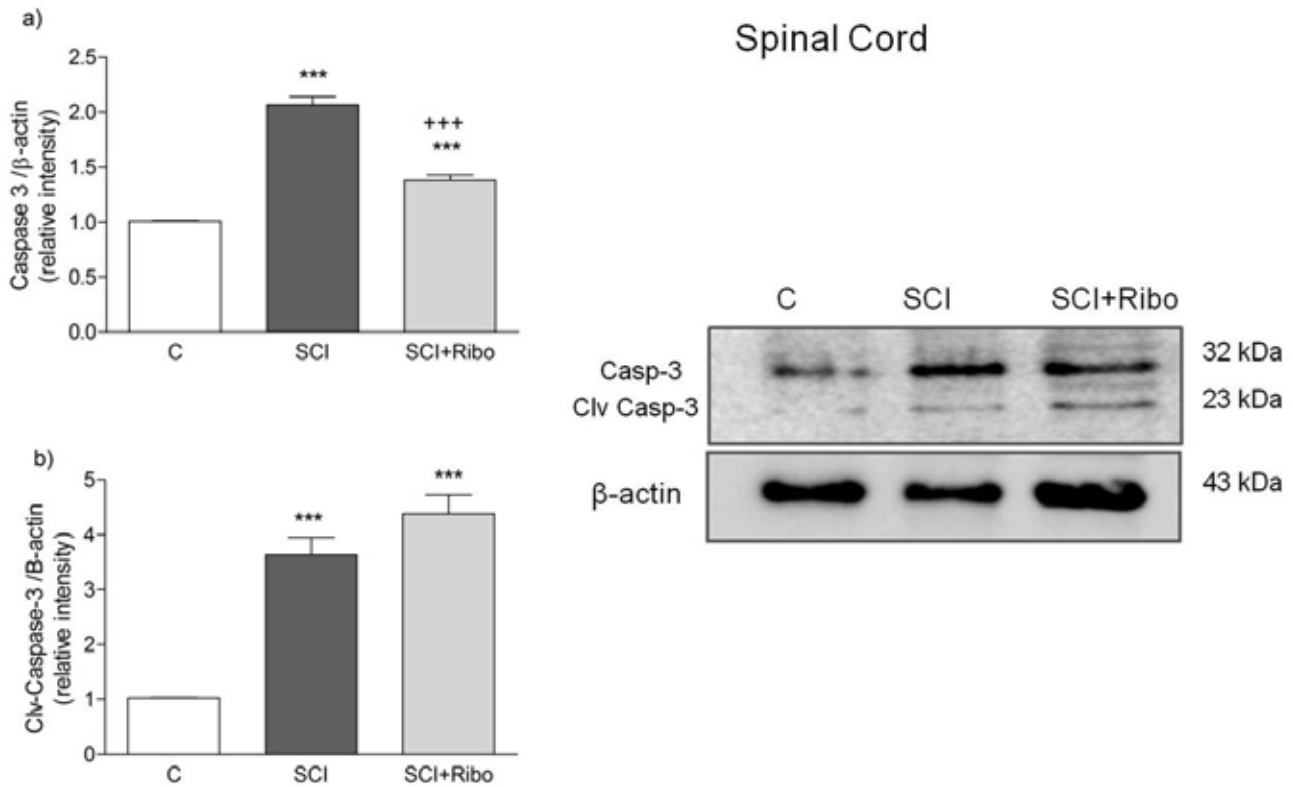


Figure 5. a, b. (a) Caspase-3 and (b) cleaved caspase-3 protein expressions determined by Western blotting in spinal cord tissues in C, SCI, and SCI+Ribo groups. Each group consisted of eight rats. Values are represented as mean±SEM \*\*\* $p < 0.001$  vs C group; +++ $p < 0.001$  vs SCI group

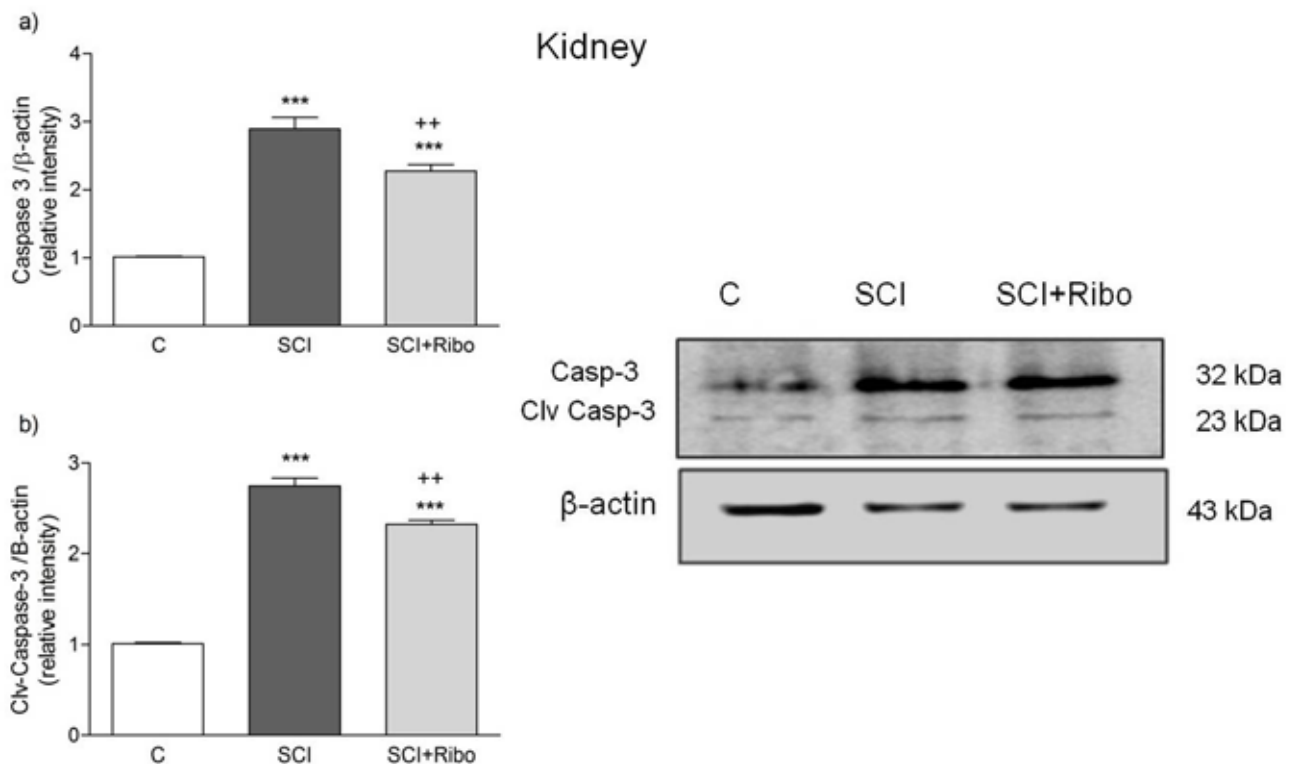
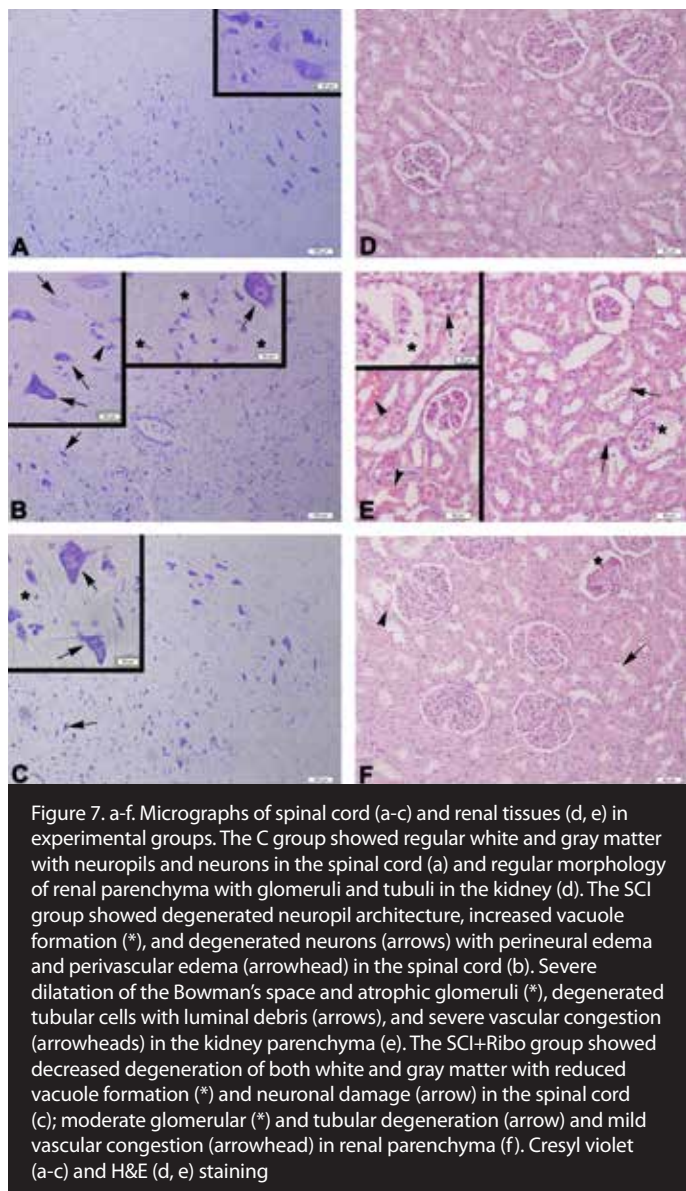


Figure 6. a, b. (a) Caspase-3 and (b) cleaved caspase-3 protein expression determined by Western blotting in kidney tissues in C, SCI, and SCI+Ribo groups. Each group consisted of eight rats. Values are represented as mean±SEM \*\*\* $p < 0.001$  vs C group; +++ $p < 0.001$  vs SCI group



where glomerular injury occurs. In the study by Shou-Shi W et al. (30), it was demonstrated that due to SCI, renal MPO activity increased, while treatment with a 2-adrenoreceptor agonist, dexmedetomidine, suppressed enzyme activity in the SCI rats. Therefore, it can be concluded that an anti-inflammatory treatment agent would be beneficial for protecting the kidney against SCI-induced damage. Similarly, in this study, an increase in MPO activity followed by a decrease, post riboflavin treatment, demonstrates the protective effects of this vitamin against inflammation.

It is well known that during apoptosis, alterations in the redox status and increases in oxidative stress, which activate caspases, play a crucial role (31). Therefore, oxidative events that occur during the pathogenesis of secondary injury after SCI leading to apoptosis is a major complicator of this process (32). Various studies have shown that irrespective of whether it is ischemia/reperfusion or trauma-related injuries on neural tissue or multiple organs, apoptosis has vigorously increased (32-35). In our previous studies, we have shown an increase in caspase-3 activity and protein expression in SCI-in-

duced spinal cord, bladder, and corpus cavernosum injuries (21, 27, 36). Moreover, an increase in renal caspase-3 activity caused by SCI demonstrated an increase in apoptosis of injured tissue while tadalafil blocked these effects (37). Additionally, Shunmugavel et al. (38) demonstrated that SCI caused renal tubular epithelial cell loss through apoptotic mechanisms. In the aforementioned study, the renal histomorphology showed an increase in caspase-3 positive cells while simvastatin treatment prevented the increase. In our study, whether it was the neural or kidney tissue, we saw a reduction in both caspase-3 activity and expression and expression of the active form (the cleaved caspase-3 protein). It is thought that these effects were due to the antioxidant and anti-inflammatory mechanisms of riboflavin. As stated above, the oxidative damage and redox changes seen in the damaged tissues were thought to activate the caspases. As the oxidative damage decreased, apoptosis also decreased, as expected.

One of the protective mechanisms used by tissues damaged by oxidation is the reduction in GSH levels. When tissues are exposed to noxious stimuli, their GSH levels become depleted (39). Thus, the main redox regulator of intracellular and extracellular compartments is GSH. GSH is able to detoxify free radicals and ROS by scavenging them or by participating in the glutathione redox system. Al-Harbi et al. (40) showed that in  $\text{CCl}_4$ -induced hepatocyte damage, GSH levels showed a significant decrease, while riboflavin treatment was able to increase the level of these antioxidants. It is hypothesized that the antioxidant functionality of riboflavin has been complemented by way of direct free radical scavenging as well as its nature of being a part of the flavoprotein family, such as glutathione reductase. SOD activity, which represents the cellular enzymatic antioxidant activity, decreases as GSH levels decrease due to increased oxidant production. In our study, whether it was a decrease in GSH levels or SOD activity, the return of these levels to normal through riboflavin treatment demonstrated the protective antioxidant effects of this vitamin.

## CONCLUSION

Based on the data collected from this experiment, for the first time, we were able to demonstrate the therapeutic effects of riboflavin on SCI injury to both neural and kidney tissue. The increase in SOD and GSH activities, along with a decrease in caspase-3 expression and MDA, MPO, and 8-OHdG levels, provided substantial evidence to prove that riboflavin possesses both antioxidant and anti-inflammatory properties.

**Ethics Committee Approval:** Ethics committee approval was received for this study from the ethics committee of Marmara University Experimental Animal Research and Implementation Centre (70.2015mar).

**Informed Consent:** Not required in this study.

**Peer-review:** Externally peer-reviewed.

**Author contributions:** Concept - S.S., M.E., G.S.; Design - S.S., M.E., G.S.; Supervision - S.S., M.E., G.S.; Resource - S.S., M.E., G.S.; Materials - S.S., M.E., G.S., O.C., E.A., F.E., M.E.E.; Data Collection and/or Processing - S.S., M.E., G.S., O.C., E.A., F.E., M.E.E.; Analysis and/or Interpretation - S.S., M.E., G.S., O.C., E.A., F.E., M.E.E.; Literature Search - S.S., M.E., G.S.; Writing - S.S., M.E., G.S.; Critical Reviews - S.S., M.E., G.S.

**Conflict of Interest:** No conflict of interest was declared by the authors.

**Financial Disclosure:** The authors declared that this study has received no financial support.

**Etik Komite Onayı:** Bu çalışma için Etik komite onayı Marmara Üniversitesi Deneysel Hayvanları Uygulama ve Araştırma Merkezi'nden alınmıştır (70.2015mar)

**Hasta Onamı:** Bu çalışma için hasta onamına gerek yoktur.

**Hakem Değerlendirmesi:** Dış Bağımsız.

**Yazar Katkıları:** Fikir - S.S., M.E., G.S.; Tasarım - S.S., M.E., G.S.; Denetleme - S.S., M.E., G.S.; Kaynaklar - S.S., M.E., G.S.; Malzemeler - S.S., M.E., G.S., O.C., E.A., F.E., M.E.E.; Veri Toplanması ve/veya işlemesi - S.S., M.E., G.S., O.C., E.A., F.E., M.E.E.; Analiz ve/veya Yorum - S.S., M.E., G.S., O.C., E.A., F.E., M.E.E.; Literatür taraması - S.S., M.E., G.S.; Yazıyı Yazan - S.S., M.E., G.S.; Eleştirel inceleme - S.S., M.E., G.S.

**Çıkar Çatışması:** Yazarlar çıkar çatışması bildirmemişlerdir.

**Finansal Destek:** Yazarlar bu çalışma için finansal destek almadıklarını beyan etmişlerdir.

## REFERENCES

- Cristante AF, Barros Filho TE, Marcon RM, Letaif OB, Rocha ID. Therapeutic approaches for spinal cord injury. *Clinics (Sao Paulo)* 2012; 67: 1219-24. [\[CrossRef\]](#)
- Boulenguez P, Vinay L. Strategies to restore motor functions after spinal cord injury. *Curr Opin Neurobiol* 2009; 19: 587-600. [\[CrossRef\]](#)
- Hulsebosch CE. Recent advances in pathophysiology and treatment of spinal cord injury. *Adv Physiol Educ* 2002; 26: 238-55. [\[CrossRef\]](#)
- Azbill RD, Mu X, Bruce-Keller AJ, Mattson MP, Springer JE. Impaired mitochondrial function, oxidative stress and altered antioxidant enzyme activities following traumatic spinal cord injury. *Brain Res* 1997; 765: 283-90. [\[CrossRef\]](#)
- Park E, Velumian AA, Fehlings MG. The role of excitotoxicity in secondary mechanisms of spinal cord injury: a review with an emphasis on the implications for white matter degeneration. *J Neurotrauma* 2004; 21: 754-74. [\[CrossRef\]](#)
- Hall ED. Antioxidant therapies for acute spinal cord injury. *Neurotherapeutics* 2011; 8: 152-67. [\[CrossRef\]](#)
- Bastani NE, Kostovski E, Sakhi AK, Karlsen A, Carlsen MH, Hjeltnes N, et al. Reduced antioxidant defense and increased oxidative stress in spinal cord injured patients. *Arch Phys Med Rehabil* 2012; 93: 2223-8. [\[CrossRef\]](#)
- Powers HJ. Riboflavin (vitamin B-2) and health. *Am J Clin Nutr* 2003; 77: 1352-60.
- Depeint F, Bruce WR, Shangari N, Mehta R, O'Brien PJ. Mitochondrial function and toxicity: role of the B vitamin family on mitochondrial energy metabolism. *Chem Biol Interact* 2006; 163: 94-112. [\[CrossRef\]](#)
- Bodiga VL, Bodiga S, Surampudi S, Boindala S, Putcha U, Nagalla B, et al. Effect of vitamin supplementation on cisplatin-induced intestinal epithelial cell apoptosis in Wistar/NIN rats. *Nutrition* 2012; 28: 572-80. [\[CrossRef\]](#)
- Al-Harbi NO, Imam F, Nadeem A, Al-Harbi MM, Korashy HM, Sayed-Ahmed MM, et al. Riboflavin attenuates lipopolysaccharide-induced lung injury in rats. *Toxicol Mech Methods* 2015; 25: 417-23. [\[CrossRef\]](#)
- Yu Z, Morimoto K, Yu J, Bao W, Okita Y, Okada K. Endogenous superoxide dismutase activation by oral administration of riboflavin reduces abdominal aortic aneurysm formation in rats. *J Vasc Surg* 2016; 64: 737-45. [\[CrossRef\]](#)
- Bertollo CM, Oliveira AC, Rocha LT, Costa KA, Nascimento EB Jr, Coelho MM. Characterization of the antinociceptive and anti-inflammatory activities of riboflavin in different experimental models. *Eur J Pharmacol* 2006; 547: 184-91. [\[CrossRef\]](#)
- Granados-Soto V, Terán-Rosales F, Rocha-González HI, Reyes-García G, Medina-Santillán R, Rodríguez-Silverio J, et al. Riboflavin reduces hyperalgesia and inflammation but not tactile allodynia in the rat. *Eur J Pharmacol* 2004; 492: 35-40. [\[CrossRef\]](#)
- Allen AR. Surgery of experimental lesion of spinal cord equivalent to crush injury of fracture dislocation of spinal column. A preliminary report. *JAMA* 1911; 57: 878-80. [\[CrossRef\]](#)
- Gale K, Kerasidis H, Wrathall JR. Spinal cord contusion in the rat: behavioral analysis of functional neurologic impairment. *Exp Neurol* 1985; 88: 123-34. [\[CrossRef\]](#)
- Hillegass LM, Griswold DE, Brickson B, Albrighson-Winslow C. Assessment of myeloperoxidase activity in whole rat kidney. *J Pharmacol Methods* 1990; 24: 285-95. [\[CrossRef\]](#)
- Beuge JA, Aust SD. Microsomal lipid peroxidation. *Methods Enzymol* 1978; 52: 302-10. [\[CrossRef\]](#)
- Beutler E. Glutathione in red blood cell metabolism. A manual of biochemical methods. Grune&Stratton, NewYork, 1975, p. 112-4.
- Myroie AA, Collins H, Umbles C, Kyle J. Erythrocyte superoxide dismutase activity and other parameters of copper status in rats ingesting lead acetate. *Toxicol Appl Pharmacol* 1986; 82: 512-20. [\[CrossRef\]](#)
- Tavukçu HH, Sener TE, Tinay I, Akbal C, Erşahin M, Cevik O, et al. Melatonin and tadalafil treatment improves erectile dysfunction after spinal cord injury in rats. *Clin Exp Pharmacol Physiol* 2014; 41: 309-16. [\[CrossRef\]](#)
- Bradford, MM. A rapid and sensitive method for the quantitation of microgram quantities of protein utilizing the principle of protein-dye binding. *Anal Biochem* 1976; 72: 248-54. [\[CrossRef\]](#)
- McCormick DB, Innis WSA, Merrill AH Jr, Bowers-Komro DM, Oka M, Chastain JL. An update on flavin metabolism in rats and humans. In: Edmondson DE, McCormick DB, (Eds.), *Flavin and flavoproteins*. New York: Walter de Gruyter, 1988. p.459-71.
- Bosch AM, Abeling NG, Ijlst L, Knoester H, van der Pol WL, Stroomer AE, et al. Brown-Vialetto-Van Laere and Fazio Londe syndrome is associated with a riboflavin transporter defect mimicking mild MADD: a new inborn error of metabolism with potential treatment. *J Inher Metab Dis* 2011; 34: 159-64. [\[CrossRef\]](#)
- McEwen ML, Sullivan PG, Rabchevsky AG, Springer JE. Targeting mitochondrial function for the treatment of acute spinal cord injury. *Neurotherapeutics* 2011; 8: 168-79. [\[CrossRef\]](#)
- Mishra J, Kumar A. Improvement of mitochondrial NAD(+)/FAD(+)-linked state-3 respiration by caffeine attenuates quinolinic acid induced motor impairment in rats: implications in Huntington's disease. *Pharmacol Rep* 2014; 66: 1148-55. [\[CrossRef\]](#)
- Cevik O, Erşahin M, Sener TE, Tinay I, Tarcan T, Çetin S, et al. Beneficial effects of quercetin on rat urinary bladder after spinal cord injury. *J Surg Res* 2013; 183: 695-703. [\[CrossRef\]](#)
- Kubota K, Saiwai H, Kumamaru H, Maeda T, Ohkawa Y, Aratani Y, et al. Myeloperoxidase exacerbates secondary injury by generating highly reactive oxygen species and mediating neutrophil recruitment in experimental spinal cord injury. *Spine (Phila Pa 1976)* 2012; 37: 1363-9. [\[CrossRef\]](#)
- Heinzelmann M, Mercer-Jones MA, Passmore JC. Neutrophils and renal failure. *Am J Kidney Dis* 1999; 34: 384-99. [\[CrossRef\]](#)
- Shou-Shi W, Ting-Ting S, Ji-Shun N, Hai-Chen C. Preclinical efficacy of Dexmedetomidine on spinal cord injury provoked oxidative renal damage. *Ren Fail* 2015; 37: 1190-7.
- Kannan K, Jain SK. Oxidative stress and apoptosis. *Pathophysiology* 2000; 7: 153-63. [\[CrossRef\]](#)
- Hausmann ON. Post-traumatic inflammation following spinal cord injury. *Spinal Cord* 2003; 41: 369-78. [\[CrossRef\]](#)



33. Wang JL, Zhang QS, Zhu KD, Sun JF, Zhang ZP, Sun JW, et al. Hydrogen-rich saline injection into the subarachnoid cavity within 2 weeks promotes recovery after acute spinal cord injury. *Neural Regen Res* 2015; 10: 958-64. [\[CrossRef\]](#)
34. Güreş B, Kertmen H, Kasim E, Yilmaz ER, Kanat BH, Sargon MF et al. Neuroprotective effects of testosterone on ischemia/reperfusion injury of the rabbit spinal cord. *Injury* 2015; 46: 240-8. [\[CrossRef\]](#)
35. Ríos C, Orozco-Suarez S, Salgado-Ceballos H, Mendez-Armenta M, Nava-Ruiz C, Santander I, et al. Anti-apoptotic effects of dapsone after spinal cord injury in rats. *Neurochem Res* 2015; 40: 1243-51. [\[CrossRef\]](#)
36. Erşahin M, Çevik Ö, Akakın D, Şener A, Özbay L, Yegen BC, et al. Montelukast inhibits caspase-3 activity and ameliorates oxidative damage in the spinal cord and urinary bladder of rats with spinal cord injury. *Prostaglandins Other Lipid Mediat* 2012; 99: 131-9. [\[CrossRef\]](#)
37. Sener TE, Tinay I, Akbal C, Erşahin M, Çevik Ö, Cadircı S, et al. Tadalafil attenuates spinal cord injury induced oxidative organ damage in rats. *Marmara Pharm J* 2014; 18: 49-55. [\[CrossRef\]](#)
38. Shunmugavel A, Khan M, Te Chou PC, Dhindsa RK, Martin MM, Copay AG, et al. Simvastatin protects bladder and renal functions following spinal cord injury in rats. *J Inflamm (Lond)* 2010; 7: 17. [\[CrossRef\]](#)
39. Wu G, Fang YZ, Yang S, Lupton JR, Turner ND. Glutathione metabolism and its implications for health. *J Nutr* 2004; 134: 489-92.
40. Al-Harbi NO, Imam F, Nadeem A, Al-Harbi MM, Iqbal M, Ahmad SF. Carbon tetrachloride-induced hepatotoxicity in rat is reversed by treatment with riboflavin. *Int Immunopharmacol* 2014; 21: 383-8. [\[CrossRef\]](#)