

Capecitabine Induced Hand-Foot Syndrome: A Systematic Review of Case Reports

Kapesitabin Kaynaklı El-Ayak Sendromu: Vaka Raporlarının Sistemik Derlemesi

Elif Aras¹ , Kamer Tecen-Yucel¹ , Aygin Bayraktar-Ekincioglu¹ , İbrahim Güllü² 

¹Department of Clinical Pharmacy, Hacettepe University School of Pharmacy, Ankara, Turkey

²Department of Medical Oncology, Hacettepe University Cancer Institute, Ankara, Turkey

ORCID IDs of the authors: E.A. 0000-0001-8667-6623, K.T.Y. 0000-0002-5381-0950, A.B.E. 0000-0002-3481-0074, İ.G. 0000-0002-6000-6311

Cite this article as: Aras E, Tecen-Yucel K, Bayraktar-Ekincioglu A, Güllü İ. Capecitabine Induced Hand-Foot Syndrome: A Systematic Review of Case Reports. Clin Exp Health Sci 2018; DOI:10.5152/clinexphealthsci.2018.1250

Abstract

Objective: Capecitabine, a prodrug of 5-fluorouracil, is currently used in the treatment of metastatic colorectal and breast cancers. The aim of this study was to review the pharmacological mechanisms, treatment strategies, and documented case reports of capecitabine-induced hand-foot syndrome (HFS).

Methods: All case reports documented in the PubMed, Web of Science, and Scopus databases up to February 2018 were searched and reviewed using the keywords capecitabine, hand-foot syndrome, and case report.

Results: The database search identified 373 articles in the literature; of these, 88 articles (having 111 case reports) in the English or Turkish language having a full-text access were included in the study. The median duration of capecitabine-induced HFS was 28 (range, 7–140) days, and the daily dose of capecitabine ranged between 850 and 5000 mg/m² in cases wherein capecitabine was applied as monotherapy (n=19). A dose reduction or treatment discontinuation, systemic or topical treatment alone or in combination, and the use of henna, vitamin E, or pyridoxine were preferred options in the treatment of HFS.

Conclusion: Health care providers and patients should be aware of developing capecitabine-induced HFS and its risk factors. Early recognition and treatment initiation for HFS are important to maintain effective chemotherapy in patients with cancer.

Keywords: Capecitabine, hand-foot syndrome, mechanism, case reports

Öz

Amaç: 5-fluorourasilin ön ilacı olan kapesitabin, günümüzde metastatik kolorektal karsinom ve meme kanseri tedavisinde kullanılmaktadır. Bu çalışmada, kapesitabin kaynaklı el-ayak sendromunun farmakolojik mekanizmaları, tedavi seçenekleri ve literatürde yer alan olgu örneklerinin derlenmesi amaçlanmıştır.

Yöntemler: Pubmed, Web of Science ve Scopus veri tabanlarında Şubat 2018'e kadar dokümanite edilen tüm olgu raporları 'kapesitabin', 'el ayak sendromu' ve 'olgu raporu' anahtar kelimeleri kullanılarak taranmıştır.

Bulgular: Elektronik veri tabanlarında 373 kayıt tespit edilmiş ve bunların arasında dili İngilizce veya Türkçe olan, tam metnine ulaşılabilen 88 makale (111 olgu raporu için) bu çalışmaya dahil edilmiştir. Kapesitabin kaynaklı el-ayak sendromu gözlenme zamanı ortancası (aralık), kapesitabin tekli tedavisi alan olgularda 28 (7-140) gün; kapesitabin doz aralığı 850 ila 5000 mg/m² olarak gözlenmiştir. Doz azaltılması veya tedavinin sonlandırılması, sistemik veya topikal tedavinin tek başına veya kombine halde uygulanması, kına, E vitamin, veya pridoksin kullanımı kapesitabin kaynaklı el-ayak sendromu tedavisinde sıklıkla tercih edilen yöntemler olmuştur.

Sonuç: Sağlık çalışanları ve hastalar, kapesitabin kaynaklı el-ayak sendromu gelişimi ve risk faktörleri konusunda farkında olmalıdır. Bu durumun erken farkedilmesi ve tedaviye erken başlanması, kanser hastalarında etkin kemoterapinin sağlanması açısından önemlidir.

Anahtar kelimeler: Kapesitabin, el-ayak sendromu, mekanizma, olgu raporu

INTRODUCTION

Capecitabine is used as an adjuvant treatment in colorectal cancer; as the first-line treatment in metastatic colorectal, gastric, pancreatic, and head and neck cancers; and as monotherapy or in combination with docetaxel in metastatic breast cancer (1). Although capecitabine is well tolerated by patients, hand-foot syndrome (HFS) is one of the common adverse events, which causes a significant degree of morbidity (2, 3). HFS was first described by Zuehlke in 1974 as an erythematous/malignant rash on the hands and toes of patients who received mitotane (4).

The incidence of capecitabine-induced HFS is approximately 50%–60%, and the severe (\geq grade 3) form of HFS occurs in approximately 10%–70% of cases. The syndrome is dose-dependent, and its occurrence is associated with the peak drug concentration and the total cumulative doses of capecitabine (5). HFS, also known as palmar-plantar erythrodysesthesia (PPE), chemotherapy-associated acral erythema, toxic palmar-plantar er-

ythema, or Burgdorf reaction, is one of the most frequent adverse events of cytotoxic chemotherapy (6). Although many cytotoxic drugs have been reported to cause HFS, it is more frequently observed in cases treated with 5-fluorouracil, liposomal doxorubicin, and cytarabine (7).

After the first-pass metabolism of capecitabine in the liver as a pro-drug, it is transformed into an active form (known as 5-fluorouracil) by thymidine phosphorylase in tumor cells, which inhibits the thymidylate synthesis in purine synthesis and blocks DNA replication and its repairing process (Figure 1) (8). The most frequently seen adverse event of capecitabine is based on dermis, which leads to vascular degeneration of keratinocytes, apoptosis, perivascular lymphocytic filtration, and edema (9). HFS manifests as dysesthesia, palmar–plantar formication, and erythema at first, and its severity increases to a painful syndrome unless treated appropriately (4, 7).

The National Cancer Institute graded the hand- and foot-related adverse effects as mild (Grade 1), moderate (Grade 2), severe (Grade 3), and life-threatening (Grade 4). Minimal skin changes, erythema, and peeling (Grade 1); moderate skin changes, swelling, and edema (Grade 2); painful erythema and swelling in the palms and soles

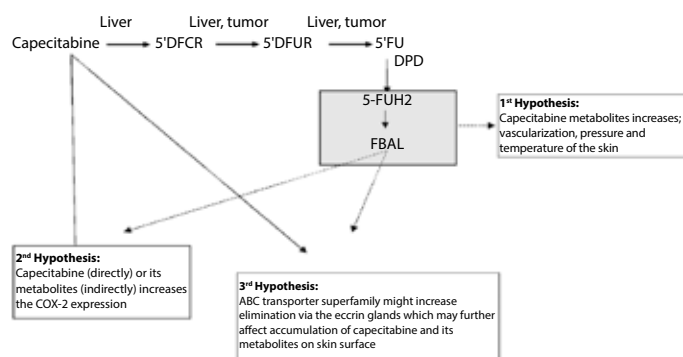


Figure 1. Possible mechanism of capecitabine induced hand foot syndrome.
 Abbreviations: CAP, capecitabine; CD, cytidine deaminase; CES, carboxylesterase ; 5'DFCR, 5'-deoxyfluorocytidine; FBAL; α-fluoro-β-alanine; 5'DFUR, 5'-deoxyfluorouridine; 5-FU, 5-fluorouracil; 5-FUH2, 5-dihydrofluorouracil; FUPA, α-fluoro-β-ureidopropionate; TP, thymidine phosphorylase; UP, uridine phosphorylase; DPD, dihydropyrimidine dehydrogenase

(Grade 3); or pain with bloating, deep peeling, and ulceration (Grade 4) can be observed in various degrees in patients (10).

The World Health Organization has classified HFS according to the symptoms, clinical appearance, and pathology. Dysesthesia and paranesthesia are accompanied by tingling in the hands and feet in Grade 1; swelling without pain in the hands and feet is observed and uncomfortable erythema occurs during walking and holding objects in Grade 2; painful erythema and swelling are observed in the palms and soles in Grade 3; and a significant increase in the severity of pain with bloating, deep peeling, and ulceration is observed in Grade 4 (10). Patient self-monitoring tools have been developed for the self-evaluation of HFS symptoms by patients (11-14).

The mechanism of capecitabine-induced HFS has not been identified in detail; however, many hypotheses have been suggested (Figure 1).

One of the hypotheses states that the excretion of capecitabine by eccrine glands leads to accumulation of its metabolites. The capecitabine metabolite level is increased due to an increased thymidylate phosphorylase in the keratocytes. It is also suggested that an increased vascularization, temperature, and pressure in the hands and feet may predispose to HFS (15).

Another hypothesis suggests that HFS occurs because of palmar–plantar cyclooxygenase (COX) inflammatory-type reaction. COX-1 is found in almost all tissues and plays an important role in the protection of the gastric mucosa. COX-2 is normally found at low levels in the cells and is induced by inflammation and mutagenic stimulation; it plays a vital role in the synthesis of prostanoids (prostaglandin, prostacyclin, thromboxane, and eicosanoids) associated with pain and inflammation (16).

Moreover, it is assumed that the carrier systems affect the absorption of capecitabine. The carriers within the membrane transport system, particularly skin membrane transport system, play a crucial role in the occurrence of capecitabine-associated toxicity along with the metabolism pathways. The ATP-binding cassette (ABC) carrier family is one of the membrane transport systems comprising proteins that transfer miscellaneous drugs, xenobiotics, and endogenous compounds from the membrane. These carrier systems eliminate antineoplastic drugs from tumor cells and prevent drug accumulation in the tumor tissue, thus leading to chemotherapy failure. Many ABC carriers play an important role in the fluoropyrimidine-based chemotherapeutic response by determining the drug concentration within the cell that leads to cutaneous reactions on hands and feet (17).

METHOD

All case reports published in the English or Turkish language before February 2018 in the PubMed, Scopus, and Web of Science databases were searched using the keywords capecitabine, hand-foot syndrome, and case report. A total of 373 articles were identified, and of these, 75 were found in the PubMed, 252 in the Scopus, and 46 in the Web of Science databases. Case reports having full-text access and providing information regarding the following criteria were included: cancer type, patient's age and sex, dose and duration of capecitabine, and treatment options for HFS. This study is a systematic review of published case reports. Therefore, a consent form was not necessary and an ethics committee approval was not sought for the study. However, the study was conducted and written according to the principles of Helsinki Declaration. The

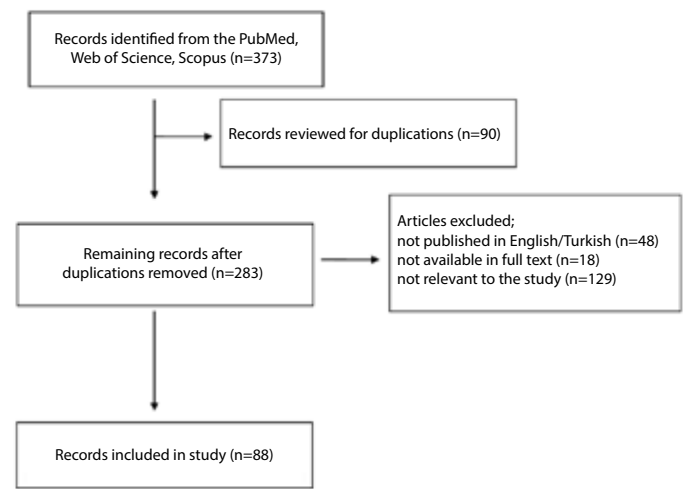


Figure 2. Flowchart of the study methodology.

Statistical Package for Social Science version 23 (IBM, New York, United States) program was used for statistical data analysis in the study. The patients' demographics were obtained from the case reports, and data were summarized using descriptive statistics.

RESULTS

Of the 373 identified articles (Figure 2), 285 were excluded due to duplicates in databases (n=90), not having full-text access (n=18), not

published in the English or Turkish language (n=48), and not relevant to the scope of the study (n=129). Therefore, 88 articles (having 111 case reports) were included in this study. Although there were variations in the characteristics of diseases, patients, dose, and duration of chemotherapy and preferred treatment for HFS (18-105) in the reported cases, information regarding the cases was summarized based on the cancer type, patient's age, patient's sex, antineoplastic treatment, capecitabine dose, HFS occurrence during the capecitabine treatment (days), and treatment options for HFS in the study (Table 1).

Table 1. Documented case reports on capecitabine-induced HFS							
Authors, year (Reference)	Cancer type	Age (year)	Sex	Antineoplastic treatment	Capecitabine dose	Occurrence of HFS during capecitabine treatment (days)	Treatment for HFS
Capecitabine monotherapy							
Gerbrecht BM., 2003 (18)	Sigmoid colon cancer	62	F	Capecitabine	2500 mg/m ² /day for 14 days then 7 days rest	After 13 and 28 days, respectively	Dose was reduced (after 28 days)
Hindenburg et al., 2003 (19)	Cervix adenocarcinoma	59	F	Capecitabine	1100 mg/m ² BID for 14 days then 7 days rest	After 7 days	Hydration and antibiotic treatment were initiated.
Schüll et al., 2003 (20)	Metastatic breast cancer	50	F	Capecitabine	2500 mg/m ² /day for 14 days then 7 days rest	N/A	N/A
Jones et al., 2003 (21)	Metastatic breast cancer	47	F	Capecitabine	2500 mg/m ² /day BID for 14 days with then 7 days rest	After 60 days	Pyridoxine 50 mg po TID was initiated.
LoRusso PM., 2003 (22)	Invasive ductal carcinoma and metastatic	46	F	Capecitabine	2500 mg/m ² / day for 14 days then 7 days rest	After 21 days	Pyridoxine 50 mg po TID was initiated at first. HFS ammonium lactate (Lac-Hydrin) lotion was started thereafter.
Clippe et al., 2003 (23)	Metastatic breast cancer	51	F	Capecitabine	2500 mg ² /day for 14 days then 7 days rest	After 8 days	Capecitabine was discontinued.
Allen et al., 2014 (24)	Rectum cancer (early stage)	63	M	Capecitabine	1250 mg/m ² BID for 14 days then 7 days rest	After 63 days	Emolient cream was initiated. When symptoms become severe, capecitabine dose reduced at the end of 5th cycle and capecitabine dose was delayed in 6 th cycle
Niemann et al., 2004 (25)	Breast cancer	61	F	Capecitabine	4000 mg/day for 14 days then 8 days rest.	N/A	N/A
Gilliam et al., 2006 (26)	Metastatic follicular thyroid cancers	49	M	Capecitabine	850 mg/m ² BID	After 25 and 180 days, respectively	Dose was reduced to 550 mg/m ² BID
Saif et al., 2006 (27)	Advanced rectal cancer	52	M	Capecitabine	1500 mg BID for 14 days then 7 days rest	After 9 day	N/A
Inui et al., 2006 (28)	Metastatic liver cancer	88	M	Capecitabine	N/A	N/A	N/A
Saif et al., 2006 (29)	Hepatocellular carcinoma	59	F	Capecitabine	1800 mg po BID for 14 days then 7 days rest	N/A	N/A
Stubblefield et al., 2006 (30)	Metastatic breast cancer	42	F	Capecitabine	2000 mg/ m ² /day	Within days of starting capecitabine	Celecoxib 200 mg po BID and gabapentin 300 mg po TID were initiated.
Vogt et al., 2006 (31)	Prostate cancer	61	M	Capecitabine	1000 mg/m ² /day for 14 days then 7 days rest	After 21 days	Capecitabine was replaced by trofosamide

Authors, year (Reference)	Cancer type	Age (year)	Sex	Antineoplastic treatment	Capecitabine dose	Occurrence of HFS during capecitabine treatment (days)	Treatment for HFS
Saini et al., 2007 (32)	Metastatic breast Cancer	56	F	Capecitabine	2500 mg/ day	After 10 days	Capecitabine was discontinued. Pyridoxine, intravenous fluids, non-steroidal antiinflammatory drugs and emollients were initiated.
Tavares-Bello R., 2007 (33)	Stage 3 adenocarcinoma	82	M	Capecitabine	N/A	After 35 days	Tacrolimus 0.1% ointment BID and emollients were initiated.
Sapp et al., 2007 (34)	Metastatic colon adenocarcinoma	67	M	Capecitabine	1000 mg/m ² BID for 14 days then 14 days rest	After 56 days	Capecitabine was discontinued
Lee et al., 2007 (35)	Gastric cancer	70	M	Capecitabine	2500 mg/day for 7 days then 7 days rest	After 60 days	Lotion was used.
Bosch et al., 2007 (36)	Dukes C2 sigmoid carcinoma	67	M	Capecitabine	2500 mg/m ² / day for 14 days	After 63 days	Capecitabine was discontinued.
Bianconi et al., 2007 (37)	Metastatic gestational trophoblastic neoplasia	29	F	Capecitabine	2500 mg/m ² BID for 14 days then 7 days rest	After about 210 days	N/A
Cho et al., 2008 (38)	Colorectal cancer	46	F	Capecitabine	2500 mg/m ² /day for 14 days then 7 days rest days	N/A	Patients receiving 6 cycles were delayed by 2 cycles and dose was decreased by 2 cycles
Yucel et al., 2008 (39)	Metastatic breast cancer	47	F	Capecitabine	N/A	N/A	Henna was used.
	Metastatic breast cancer	48	F	Capecitabine	N/A	N/A	Henna was used.
	Metastatic breast cancer	59	F	Capecitabine	N/A	N/A	Henna was used.
	Metastatic breast cancer	73	F	Capecitabine	N/A	N/A	Henna was used.
	Metastatic colon cancer	68	F	Capecitabine	N/A	N/A	Henna was used.
Trindade et al., 2008 (40)	Metastatic sigmoid colon	56	M	Capecitabine	2000 mg/day BID	7 th cycle	N/A
Vickers et al., 2008 (41)	Stage II moderately invasive adenocarcinoma	49	M	Capecitabine	N/A	After 63 days	Capecitabine dose was reduced.
	Stage III sigmoid colon cancer	58	F	Capecitabine	N/A	3 rd cycle	4 th cycle was delayed and the dose was reduced by 50%.
	Stage III colon cancer	54	M	Capecitabine	N/A	Before 3 rd cycle	Capecitabine dose was reduced.
Surjushe et al., 2008 (42)	Adenocarcinoma of the common bile duct	50	F	Capecitabine	500 mg BID	After 2 nd cycle	Topical and systemic antibiotics were initiated and capecitabine dose was reduced

Table 1. Documented case reports on capecitabine-induced HFS (Continued)

Authors, year (Reference)	Cancer type	Age (year)	Sex	Antineoplastic treatment	Capecitabine dose	Occurrence of HFS during capecitabine treatment (days)	Treatment for HFS
Goutos et al., 2009 (43)	Colon Dukes B adenocarcinoma	71	M	Capecitabine	N/A	After 90 days	Treatment was discontinued and pyridoxine 50 mg po TID, silver sulfadiazine cream (1%) and silicone-coated nylon dressings were initiated.
Endrizzi et al., 2009 (44)	SCC	70	M	Capecitabine	1150 mg po BID	N/A	N/A
	SCC and BCC	72	M	Capecitabine	1500 mg/day	N/A	N/A
	SCC and BCC	50	M	Capecitabine	1050/m ² /day	N/A	N/A
Villalón et al., 2009 (45)	Metastatic breast cancer	58	F	Capecitabine	2500 mg/m ² /day	4 th cycle	Capecitabine was discontinued
Lopez et al., 2010 (46)	Metastatic invasive ductal carcinoma	49	F	Capecitabine	1500 mg/m ² /day BID	Several days after the 2 nd cycle	Emollients and topical corticosteroids were initiated and capecitabine dose was reduced to 1000 mg/m ² BID. Capecitabine was discontinued if symptoms are not resolved.
Wong et al., 2009 (47)	Metastatic nasopharyngeal carcinoma	62	M	Capecitabine	1700 mg BID for 14 days then 7 days rest	N/A	No intervention
Baena-Cañada et al., 2010 (48)	Metastatic invasive ductal carcinoma of breast	66	F	Capecitabine	1000 mg/m ² BID for 14 days, every 22 day	After 132 days	Dose was decreased
Disel et al., 2010 (49)	Metastatic gastric cancer	65	M	Capecitabine	1000 mg/m ² /day BID for 14 days then 7 days rest	After 94 days	Capecitabine was discontinued and supportive treatment was initiated.
Gafson et al., 2010 (50)	Colon cancer	66	M	Capecitabine	1250 mg /m ² BID for 14 days then 7 days rest	After 63 days	Pyridoxine 50 mg po TID was initiated.
Vasudevan B., 2010 (51)	Adenocarcinoma of stomach	59	M	Capecitabine	2000 mg BID for 14 days then 7 days rest.	After 42 days	Topical emollient was initiated
Bayraktar et al., 2011 (52)	Breast cancer	93	F	Capecitabine	1500 mg/day	After 2 nd cycle	N/A
Gordon et al., 2011 a (53)	Cecal adenocarcinoma	57	M	Capecitabine	N/A	After 2 nd cycle	Antibiotics was started
Serdar et al., 2011 (54)	Colon carcinoma	68	M	Capecitabine	N/A	3 rd cycle	Topical steroid was initiated.
Qiao et al., 2012 (55)	Advanced rectal cancer	59	F	Capecitabine	N/A	After 9 days	Topical urea cream was initiated.
Cruz et al., 2012 (56)	Metastatic colon cancer	53	M	Capecitabine	1000 mg/m ² BID for 14 days then 7 days rest	After 21 days	Capecitabine was discontinued.
Sanghia et al., 2012 (57)	Breast cancer	30	F	Capecitabine	500 mg for 14 days then 7 days rest	After 87 days	Dose was decreased and topical emollient was initiated.
Chan et al., 2012 (58)	Colon Dukes C adenocarcinoma	42	F	Capecitabine	2000 mg BID for 14 days then 7 days rest	After 21 days	Dose was decreased to 1500 mg BID
Lipshitz et al., 2012 (59)	Sigmoid colon cancer	82	M	Capecitabine	N/A	After about 120 days	Capecitabine was discontinued
Tanaka et al., 2013 (60)	Metastatic breast cancer	62	F	Capecitabine	2400 mg/day	N/A	N/A

Table 1. Documented case reports on capecitabine-induced HFS (Continued)

Authors, year (Reference)	Cancer type	Age (year)	Sex	Antineoplastic treatment	Capecitabine dose	Occurrence of HFS during capecitabine treatment (days)	Treatment for HFS
Marinelli et al., 2013 (61)	Hepatocellular carcinoma	53	F	Capecitabine	500 mg BID	After 30 days	Capecitabine was discontinued temporarily and emollient, urea-based creams were initiated.
Inokuchi et al., 2013 (62)	Metastatic invasive ductal carcinoma	75	F	Capecitabine	1657 mg/m ² /day for 14 days then 7 days rest	After 63 days	Prophylactic pyridoxine and obetasol propionate (a superpotent steroid) were initiated. If symptoms are not resolved 0.1% adapalene gel BID was initiated.
Perri et al., 2013 (63)	Squamous cell carcinoma of the head and neck	N/A	N/A	Capecitabine	500 mg/m ² BID for 14 days then 7 days rest.	After 42 days	Capecitabine was discontinued
Mishra et al., 2013 (64)	Per ampullary carcinoma	62	M	Capecitabine	N/A	At the beginning of 3rd cycle	Pyridoxine tablet and topical steroid were initiated
Ilyas et al., 2014 (65)	Pancreas adenocarcinoma	53	F	Capecitabine	1500 mg for 14 days po BID then 7 days rest	After 42 days	Henna was used.
Prakasam et al., 2014 (66)	Advanced gastric cancer	65	M	Capecitabine	500 mg BID for 14 days then 7 days rest	After 14 days	Prophylactic antibiotics (cefotaxime and metronidazole) were initiated to prevent secondary infection of the skin lesions; topical emollients (liquid paraffin), oral steroids, Vitamin E and B complex and non-steroidal anti-inflammatory drug (diclofenac) were initiated
Parikh et al., 2015 (67)	Cutaneous squamous cell carcinoma	30	F	Capecitabine	500 mg/m ² BID for 14 days then 7 days rest.	N/A	Capecitabine dose was reduced
Elmas et al., 2016 (68)	Metastatic ductal breast carcinoma	62	F	Capecitabine	N/A	After 3 rd cycle	Dose was decreased and mometazon furoate pomade and moisturizer were initiated
Li et al., 2016 (69)	Colorectal carcinoma	74	F	Capecitabine	1250 mg/m ² BID for 14 days then 7 days rest	After 21 days	Capecitabine was discontinued and mometazon furoate cream, topical retinoid cream and hydroxychloroquine (during 9 days) were initiated.
Rovere et al., 2017 (70)	Metastatic rectal cancer	47	M	Capecitabine	2000 mg/m ² /day	After about 240 days	Capecitabine was discontinued
Mazza et al., 2017 (71)	Rectal adenocarcinoma and liver metastasis	60	M	Capecitabine	N/A	After 150 days	Capecitabine dose was reduced
Combination treatment with capecitabine							
Chen et al., 2003 (72)	Breast cancer	40	F	Capecitabine and docetaxel	1250 mg/m ² BID for 14 days then 7 days rest.	After 30 days	Potassium permanganate solution (for nail disorder) and gentamicin ointment was initiated.
	Breast cancer	52	F	Capecitabine and docetaxel	1250 mg/m ² BID for 14 days then 7 days rest.	After 30 days	Potassium permanganate solution (for nail disorder) and gentamicin ointment was initiated.
	Breast cancer	50	F	Capecitabine and docetaxel	1250 mg/m ² BID for 14 days then 7 days rest.	After 30 days	Potassium permanganate solution (for nail disorder) and gentamicin ointment was initiated.

Table 1. Documented case reports on capecitabine-induced HFS (Continued)

Authors, year (Reference)	Cancer type	Age (year)	Sex	Antineoplastic treatment	Capecitabine dose	Occurrence of HFS during capecitabine treatment (days)	Treatment for HFS
Uslu et al., 2005 (73)	Metastatic invasive ductal carcinoma	68	F	Capecitabine and docetaxel	N/A	After about 210 days	Capecitabine was discontinued. Permanganate bath, emollient cream and 500 mg/day po pyridoxine were initiated.
Kara et al., 2005 (74)	Metastatic ductal carcinoma	72	F	Capecitabine, docetaxel and zoledronate	N/A	After 2 nd cycle	The treatment was stopped and vitamin E was initiated at dose of 300 mg/day.
	Metastatic ductal carcinoma	48	F	Capecitabine and docetaxel	N/A	After 2 nd cycle	Vitamin E was initiated at dose of 300 mg/day.
	Metastatic ductal carcinoma	46	F	Capecitabine and docetaxel	N/A	After 3 rd cycle	Vitamin E initiated started at 300 mg/day
	Invasive ductal carcinoma	40	F	Capecitabine and docetaxel	N/A	3 rd cycle	Vitamin E was initiated at dose of 300 mg/day.
	Metastatic invasive ductal carcinoma	50	F	Capecitabine and docetaxel	N/A	3 rd cycle	Vitamin E was initiated at 300 mg/day.
Gilliam et al., 2006 (26)	Metastatic FTC	41	F	Capecitabine and doxorubicin	Capecitabine 1000 mg/m ² BID	After 84 days	Capecitabine was discontinued.
Tham et al., 2006 (75)	Grade-2 ductal carcinoma	51	F	Capecitabine and whole-brain radiation	2500 mg/m ² /day for 14 days then 7 days rest.	After about 400 days	Capecitabine was discontinued.
Sapp et al., 2007 (34)	Gastric adenocarcinoma	63	M	Capecitabine and oxaliplatin	1000 mg/m ² po BID for 14 days then 7 days rest	After 11 days	Capecitabine was discontinued.
Goyal et al., 2007 (76)	Metastatic hepatocellular carcinoma	50	M	Capecitabine and thalidomide	1500 mg/ day	After 60 days	All medications were discontinued. Emollients and analgesic cream were initiated.
Yucel et al., 2008 (39)	Metastatic breast cancer	49	F	Capecitabine and docetaxel	N/A	N/A	Henna was used.
	Metastatic breast cancer	33	F	Capecitabine and docetaxel	N/A	N/A	Henna was used.
	Metastatic breast cancer	50	F	Capecitabine and docetaxel	N/A	N/A	Henna was used.
	Metastatic breast cancer	59	F	Capecitabine and docetaxel	N/A	N/A	Henna was used
	Metastatic breast cancer	33	F	Docetaxel, Capecitabine	N/A	N/A	Henna was used.
Shigekawa et al., 2008 (77)	Metastatic breast cancer	44	F	Capecitabine and trastuzumab	1650 mg/m ² BID for 21 days then 7 days rest.	After 112 days	Capecitabine dose was reduced to 1800 mg/day
Saif et al., 2008 (78)	Gastric adenocarcinoma	69	M	Capecitabine and radiotherapy	1000 mg BID po for 7 days then 7 days rest	After 56 days	N/A
Karatay et al., 2008 (79)	Ductal carcinoma	55	F	Capecitabine and paclitaxel	1250 mg/m ² BID	3 rd cycle	Capecitabine dose was reduced to 1000 mg/m ² BID
Shahrokni et al., 2009 (80)	Metastatic colon cancer	55	M	Capecitabine and gemcitabine	N/A	N/A	Aggressive skin care and pyridoxine were initiated.

Table 1. Documented case reports on capecitabine-induced HFS (Continued)

Authors, year (Reference)	Cancer type	Age (year)	Sex	Antineoplastic treatment	Capecitabine dose	Occurrence of HFS during capecitabine treatment (days)	Treatment for HFS
Mignogna et al., 2009 (81)	Breast cancer	61	F	Capecitabine, lapatinib, and zoledronic acid	2000 mg/m ² po qd for 14 days then 7 days rest days	After 28 days	Capecitabine dose was reduced.
Baretta et al., 2009 (82)	Breast cancer	59	M	Capecitabine and trastuzumab	N/A	N/A	Aloe vera was used.
Vrdoljak et al., 2010 (83)	Metastatic breast cancer	50	F	Capecitabine and ixabepilone	1000 mg/m ² BID for 14 days then 7 days rest	After 126 and 231 days, respectively	At first, capecitabine dose was reduced by 25% of the total dose. At second, 50% of the initial capecitabine dose.
Yoshida et al., 2011 (84)	Metastatic colon cancer	43	M	Capecitabine, oxaliplatin and bevacizumab	1000 mg/m ² BID for 14 days then 7 days rest	After 121 days	No intervention
Hoesly et al., 2011 (85)	Metastatic breast cancer	61	F	Capecitabine and lapatinib	1250 mg/m ² /day BID	After 1094 days	Ammonium lactate cream 12% was initiated.
Akash et al., 2011 (86)	Stage-III breast carcinoma	50	F	Capecitabine, lapatinib and docetaxel	900 mg/day po	14 days after 4 th cycle	Chemotherapy was discontinued and po pyridoxine, i.v ceftriaxone, i.v metronidazole, po B-vit complex, rabeprazole, iron supplements, urease cream, moisturizing cream and gentian violet paint for local application were used
Ferreira et al., 2011 (87)	Metastatic HER2 negative breast cancer	55	F	Capecitabine and bevacizumab	3000 mg/day for 14 days then 7 days rest	After 176 days	Capecitabine dose was reduced by 25%
Gordon et al., 2011 b (53)	Sigmoid colon cancer	59	M	Capecitabine, oxaliplatin and folinic acid	N/A	N/A	Topical steroid preparations was used.
Richey et al., 2011 (88)	Metastatic RCC	56	M	Capecitabine and gemcitabine	1750 mg/m ² /day for 21 days of a 28 day cycle	After about 300 days	Capecitabine dose was reduced.
Ozkan et al., 2011 (89)	Breast cancer	53	F	Capecitabine and trastuzumab	After about 4 years	N/A	Capecitabine was discontinued.
Al-Ahwal MS., 2012 (90)	Metastatic rectum adenocarcinoma	53	M	Capecitabine and oxaliplatin	Capecitabine 1000 mg/m ² BID for 14 days	After 30 days	Paracetamol, tramadol and topical emollient creams were initiated.
Sanghia et al., 2012 (57)	Adenocarcinoma colon	66	M	Capecitabine and leucovorine	N/A	After 30 days	Capecitabine was discontinued. Topical steroids and pyrodoxine injection were initiated.
Rolski et al., 2012 (91)	Metastatic breast cancer	52	F	Capecitabine and lapatinib	2000 mg/m ²	After about 550 days	Capecitabine was discontinued.
Yan et al., 2012 (92)	Metastatic hepatocellular carcinoma	60	M	Capecitabine and nimotuzumab	1000 mg/m ² BID for 14 days then 7 days rest	After 98 days	N/A
Uleer et al., 2012 (93)	Breast cancer	29	F	Capecitabine and trastuzumab	N/A	N/A	Capecitabine was discontinued for 6 weeks and then started with a 50% dose reduction.
Vincent et al., 2013 (94)	Metastatic breast carcinoma	45	F	Capecitabine and bevacizumab	2000 mg po BID for 14 days then 7 days rest	N/A	Dose adjustment for capecitabine was not required.

Table 1. Documented case reports on capecitabine-induced HFS (Continued)

Authors, year (Reference)	Cancer type	Age (year)	Sex	Antineoplastic treatment	Capecitabine dose	Occurrence of HFS during capecitabine treatment (days)	Treatment for HFS
Lal HS., 2014 (95)	Breast cancer	55	F	Capecitabine and paclitaxel	500 mg po TID for 14 days then 7 days rest	After 42 days	Emollient cream, including aloe vera and vitamin E was initiated.
Yoshida et al., 2014 (96)	Metastatic rectum cancer	62	M	Capecitabine and oxaliplatin	1000 mg/m ² BID for 14 days then 7 days rest	After 84 days	N/A
Kigen et al., 2015 (97)	Metastatic colon cancer duke C	62	F	Capecitabine and oxaliplatin (XELOX)	1500 mg BID	After 84 days	Capecitabine was discontinued and vitamin supplement was initiated.
Matsuda et al., 2015 (98)	Metastatic colon cancer	60	M	Capecitabine, oxaliplatin and bevacizumab	N/A	After 2 nd cycle	N/A
Chavarri-Guerra et al., 2015 (99)	Breast cancer	65	F	Capecitabine and bevacizumab	N/A	During the 1 st cycle and after 3 rd cycle	Topical agents were initiated at 1 st cycle and dose was delayed at 3 rd cycle
Del Re et al., 2015 (100)	HER2 positive ductal carcinoma	37	F	Capecitabine and trastuzumab	1250 mg/m ² BID for 14 days then 7 days rest	After 7 days	Capecitabine was discontinued.
Takeshita et al., 2015 (101)	Metastatic rectal cancer	66	F	Capecitabine and bevacizumab	N/A	N/A	Dose intervals of therapy was extended and capecitabine dose was reduced.
Lightowlers et al., 2015 (102)	N/A	47	M	Capecitabine and oxaliplatin	N/A	N/A	N/A
Hashidaa et al., 2017 (103)	Metastatic lung cancer and advanced rectal cancer	53	F	Capecitabine, irinotecan and bevacizumab	1600 mg/m ² /day for 14 days then 7 days rest	After 121 days	N/A
Hadzavdic et al., 2017 (104)	Metastatic adenocarcinoma of colon	63	M	Capecitabine, irinotecan and bevacizumab	N/A	During 2 nd cycle	A skin barrier cream, moisturized ointments and potent topical corticosteroids were initiated (but symptoms were not relieved). Then, capecitabine was discontinued.
Singh et al., 2018 (105)	Metastatic intrahepatic cholangio-carcinoma	52	F	Capecitabine and irinotecan	850 mg/m ²	Five days after receiving the 2 nd cycle	Capecitabine was discontinued.

N/A: Not Available; F: Female; M: Male; i.v: intravenous; po: per oral; BID: 2 times a day; TID: 3 times a day; SCC: squamous cell carcinoma; BCC: single basal cell carcinoma.

A total of 111 patients presented in the case reports were reviewed in this study, of which, 67 (60%) were female, and the mean (\pm standard deviation) age was 56.14 \pm 11.9 years (52.9 \pm 11.9 years in females and 61.2 \pm 9.6 years in males). The most commonly seen cancer types were breast cancer (n=48; 43.24%), colon cancer (n=23; 20.72%), rectal cancer (n=8; 7.20%), hepatocellular carcinoma (n=6; 5.40%), and gastric cancer (n=6; 5.40%).

Capecitabine-induced HFS occurred between 7 and 240 days of capecitabine monotherapy (n=62 cases). Among the cases receiving capecitabine monotherapy, the median (range) duration for the occurrence of capecitabine-induced HFS (n=24 cases) was 28 (7–140) days, and the daily dose of capecitabine (n=19 cases) ranged between 850 and 5000 mg/m².

The combination of treatment strategies (n=34; 30.63%: systemic treatment \pm topical treatment \pm dose reduction \pm treatment discontinued), capecitabine dose reduction (n=15; 13.51%), capecitabine discontinuation (n=15; 13.51%), the use of henna (n=11; 9.90%), the use of topical treatment (n=6; 5.40%), the use of vitamin E (n=4; 3.60%), and the use of pyridoxine treatment (n=2; 1.80) were observed in 111 cases. There was no information about the HFS treatment in 18 cases. Furthermore, the use of antibiotic therapy (n=1) and capecitabine replacement with other chemotherapeutic (n=1 cases) were seen, and no intervention was implemented in 3 cases.

The risk factors of developing HFS were previously indicated as advanced age, female sex, performance status, continuous chemo-

Table 2. Recommended dose adjustment of capecitabine in hand-foot syndrome

Hand-Foot Syndrome		Capecitabine dose adjustment			
Grade	Characteristics	1 st occurrence	2 nd occurrence	3 rd occurrence	4 th occurrence
1	Skin changes that not interfere with activities of daily living (eg, numbness, dysesthesia, paresthesia, tingling, erythema)	%100 dose	%100 dose	%100 dose	%100 dose
2	Pain that affects activities of daily living and skin changes (eg, erythema, swelling)	Interrupt the treatment and give the next dose of %100	Interrupt the treatment and give the next dose of %75	Interrupt the treatment and give the next dose of %50	Discontinue treatment permanently
3	Severe skin changes (eg, damp splashes, ulceration, blistering) accompanied by pain that severely affects activities of daily living	Interrupt the treatment and give the next dose of %75	Interrupt the treatment and give the next dose of %50	Discontinue treatment permanently	Discontinue treatment permanently

therapy infusion, a history of fluorinated pyrimidine administration, exposure to total body irradiation, preexisting diabetes, peripheral arterial disease and/or peripheral neuropathy, the use of tyrosine kinase inhibitors, hemoglobin level < 12 mg/dl, white blood cell counts, and the number of organs affected (106-110).

The HFS manifestations can be seen in various degrees representing differences in the occurrence of scars and time to healing. A loss of fingerprints associated with HFS has recently been reported in a male patient with metastatic nasopharyngeal carcinoma treated with capecitabine for >3 years (10).

There were no effective strategies established for the prevention or HFS treatment since the underlying mechanism is not fully elucidated in the literature. Therefore, dose reduction or cessation or postponing of therapy can be considered, particularly in patients with Grade 2 symptoms (111). The Grade 2 symptoms may rapidly progress, and symptom relief may require longer time when it reaches Grade 3. This situation can lead to the cessation of chemotherapy; therefore, an early detection of Grade 2 symptoms is crucial for dose adjustment (Table 2) (15-17; 11-14; 112).

The treatment options for HFS were not used or were not indicated in 20 case reports included in the study. Many treatment strategies were investigated to alleviate and treat HFS symptoms including the use of antiperspirants, topical urea-lactic acid mixture, or vitamin E (113-114). Pyridoxine was used to relieve paresthesia and reduce the syndrome severity (106); however, studies showed that the use of pyridoxine as prophylaxis is not as effective as it was considered (115-116). The use of softening/moisturizing creams as a prophylactic or therapeutic option was recommended for all grades of HFS, particularly Grade 1 (117), which may prevent or delay dose reduction during the treatment. COX-2 inhibitors (6) and topical or systemic use of corticosteroids were shown to be effective in the prophylaxis and treatment of HFS; however, the effectiveness of steroids in capecitabine-induced HFS has not been proven yet (118-119) due to the risk of skin thinning and aggravation of symptoms caused by the long-term use (117). Immersing hands and feet in cold water and avoiding skin irritants and changes in temperature and/or pressure are examples of non-pharmacological treatment strategies (120).

DISCUSSION

Many case reports on capecitabine-induced HFS have been documented in the literature. The first case report on capecitabine-related

HFS was published in 2003, and the number of cases has increased recently (22). The summary of product characteristics included information about capecitabine-induced HFS. However, there is no specific information on the occurrence and treatment of HFS (1). The case reports included in the study had diverse information regarding patient’s sex, age, medical history, performance status, and dose and duration of capecitabine treatment. Therefore, it was difficult to identify particular risk factors for developing HFS.

Female sex is recognized as a risk factor for developing HFS. In this systematic review, 67 (60%) of the 111 cases were women, emphasizing the importance of this risk factor.

It was difficult to identify any correlation between the total and/or exposed cumulative dose of capecitabine and the first occurrence of HFS during treatment since there was no detailed information regarding the capecitabine dose and duration of treatment in these cases. In addition, patients’ weight, previous chemotherapy cycles, and other confounding factors could not be extracted from the case reports to conclude this finding.

It was identified that capecitabine-induced HFS occurred between 7 and 240 days of the treatment. Among the treatment strategies used for HFS, pyridoxine, vitamin E, emollient creams, and henna were likely to be effective in alleviating the symptoms. However, the effective dose and duration of these treatments have not been established (113-116).

HFS is not a life-threatening complication, but it significantly reduces the patient’s quality of life. When HFS does occur, certain problems with compliance may arise, and cessation of chemotherapy may be required. Therefore, early recognition of HFS is important for maintaining the patient’s quality of life and continuity of treatment. Patient self-monitoring tools have been developed for assessing HFS symptoms, which can contribute to an active patient involvement in the chemotherapy process (11-14).

CONCLUSION

Capecitabine-induced HFS is a cutaneous skin reaction that affects the palms and/or soles of hands and is frequently observed with the use of cytotoxic drugs, particularly 5-fluorouracil, capecitabine, liposomal doxorubicin, and cytarabine.

Considering the published studies, it is difficult to indicate the best treatment options for capecitabine-induced HFS since different strategies have been used for its management. Therefore, additional data from further clinical trials and/or meta-analysis are required to establish the most appropriate treatment strategy for HFS in different patient populations.

It is essential that patients should be informed about the early signs and symptoms of HFS, and they be closely monitored by health care providers for early diagnosis and appropriate management of HFS.

In conclusion, health care providers and patients should be aware of developing capecitabine-induced HFS, its associated risk factors, and early initiation of treatment options during chemotherapy.

Peer-review: Externally peer-reviewed.

Author contributions: Concept – E.A., A.BE., İ.G.; Design – E.A., A.BE., K.TY.; Supervision – A.BE., İ.G.; Resource – E.A., K.TY.; Materials – E.A., K.TY., A.BE.; Data Collection and/or Processing – E.A., K.TY.; Analysis and/or Interpretation – E.A., K.TY., A.BE., İ.G.; Literature Search – E.A., K.TY.; Writing – E.A., K.TY., A.BE., İ.G.; Critical Reviews – A.BE., İ.G.

Conflict of Interest: No conflict of interest was declared by the authors.

Financial Disclosure: The authors declared that this study received no financial support.

REFERENCES

- Laboratory, R, Xeloda[®] product information. Retrieved from <http://www.rocheusa.com/products/xeloda/pi.pdf>, April 2006.
- Hennessy BT, Gauthier AM, Michaud LB, Hortobagyi G, Valero V. Lower dose capecitabine has a more favorable therapeutic index in metastatic breast cancer: retrospective analysis of patients treated at M. D. Anderson Cancer Center and a review of capecitabine toxicity in the literature. *Ann Oncol* 2005; 16(8): 1289-96. [CrossRef]
- Pendharkar D, Goyal H. Novel & effective management of capecitabine induced Hand Foot Syndrome. *J Clin Oncol* 2004. 22(14_suppl): 8105.
- Miller KK, Gorcey L, McLellan BN. Chemotherapy-induced hand-foot syndrome and nail changes: a review of clinical presentation, etiology, pathogenesis, and management. *J Am Acad Dermatol* 2014; 71(4): 787-94. [CrossRef]
- Gressett SM, Stanford BL, Hardwicke F. Management of hand-foot syndrome induced by capecitabine. *J Oncol Pharm Pract* 2006; 12(3): 131-41. [CrossRef]
- Scheithauer W, Blum J. Coming to grips with hand-foot syndrome. Insights from clinical trials evaluating capecitabine. *Oncology (Williston Park)* 2004; 18(9): 1161-8, 1173; discussion 1173-6, 1181-4.
- Webster-Gandy JD, How C, Harrold K. Palmar-plantar erythrodysesthesia (PPE): a literature review with commentary on experience in a cancer centre. *Eur J Oncol Nurs* 2007; 11(3): 238-46. [CrossRef]
- Queckenberg C, Erlinghagen V, Baken BC, Van Os SH, Wargenau M, Kubeš V, et al. Pharmacokinetics and pharmacogenetics of capecitabine and its metabolites following replicate administration of two 500 mg tablet formulations. *Cancer Chemother Pharmacol* 2015; 76(5): 1081-91. [CrossRef]
- Nagore E, Insa A, Sanmartín O. Antineoplastic therapy-induced palmar plantar erythrodysesthesia ('hand-foot') syndrome. Incidence, recognition and management. *Am J Clin Dermatol* 2000; 1(4): 225-34. [CrossRef]
- Cohen PR. Capecitabine-Associated Loss of Fingerprints: Report of Capecitabine-Induced Adermatoglyphia in Two Women with Breast Cancer and Review of Acquired Dermatoglyphic Absence in Oncology Patients Treated with Capecitabine. *Cureus* 2017; 9(1): e969. [CrossRef]
- Mikoshiha N, Yamamoto-Mitani N, Ohki T, Asaoka Y, Yamaguchi H, Obi S, et al. A simple home-based self-monitoring tool for early detection of hand-foot syndrome in cancer patients. *Jpn J Clin Oncol* 2016. [CrossRef]
- Murugan K, Ostwal V, Carvalho MD, D'souza A, Achrekar MS, Govindarajan S, et al. Self-identification and management of hand-foot syndrome (HFS): effect of a structured teaching program on patients receiving capecitabine-based chemotherapy for colon cancer. *Support Care Cancer* 2016; 24(6): 2575-81. [CrossRef]
- Anderson RT, Keating KN, Doll HA, Camacho F. The Hand-Foot Skin Reaction and Quality of Life Questionnaire: An Assessment Tool for Oncology. *Oncologist* 2015; 20(7): 831-8. [CrossRef]
- Tkeda K, Shigemasa T, Shirai M, Yamanda T. [Assessment of hand-foot syndrome in cancer outpatients undergoing chemotherapy]. *Gan To Kagaku Ryoho* 2012; 39 Suppl 1: 74-6.
- Milano G, Etienne-Grimaldi MC, Mari M, Lassalle S, Formento JL, Francoual M, et al. Candidate mechanisms for capecitabine-related hand-foot syndrome. *Br J Clin Pharmacol* 2008; 66(1): 88-95. [CrossRef]
- Lin E, Morris JS, Ayers GD. Effect of celecoxib on capecitabine-induced hand-foot syndrome and antitumor activity. *Oncology (Williston Park)* 2002; 16(12 Suppl No 14): 31-7.
- Nies AT, Magdy T, Schwab M, Zanger UM. Role of ABC transporters in fluoropyrimidine-based chemotherapy response. *Adv Cancer Res* 2015; 125: 217-43. [CrossRef]
- Gerbrecht BM. Current Canadian experience with capecitabine: partnering with patients to optimize therapy. *Cancer Nurs* 2003; 26(2): 161-7. [CrossRef]
- Hindenburg AA, Matthews L. Complete and sustained remission of refractory cervical cancer following a single cycle of capecitabine. A case report. *Int J Gynecol Cancer* 2003; 13(6): 898-900. [CrossRef]
- Schull BW, Scheithauer W, Kornek GV. Capecitabine as salvage therapy for a breast cancer patient with extensive liver metastases and associated impairment of liver function. *Onkologie* 2003; 26(6): 578-80.
- Jones KL, Valero V. Capecitabine-induced pancreatitis. *Pharmacotherapy* 2003; 23(8): 1076-8. [CrossRef]
- LoRusso PM. Capecitabine and PPE syndrome: a case report. *Breast J* 2003; 9(1): 64-5. [CrossRef]
- Clippe C, Freyer G, Milano G, Trillet-Lenoir V. Lethal toxicity of capecitabine due to abusive folic acid prescription? *Clin Oncol (R Coll Radiol)* 2003; 15(5): 299-300. [CrossRef]
- Allen J, Williamson S. Over compliance with capecitabine oral chemotherapy. *Int J Clin Pharm* 2014; 36(2): 271-3. [CrossRef]
- Niemann B, Rochlitz C, Herrmann R, Pless M. Toxic encephalopathy induced by capecitabine. *Oncology* 2004; 66(4): 331-5. [CrossRef]
- Gilliam LK, Kohn AD, Lalani T, Swanson PE, Vasko V, Patel A, et al. Capecitabine therapy for refractory metastatic thyroid carcinoma: a case series. *Thyroid* 2006; 16(8): 801-10. [CrossRef]
- Saif MW, Elfiky A, Diasio R. Hand-foot syndrome variant in a dihydropyrimidine dehydrogenase-deficient patient treated with capecitabine. *Clin Colorectal Cancer* 2006; 6(3): 219-23. [CrossRef]
- Inui T, Asakawa A, Morita Y, Mizuno S, Natori T, Kawaguchi A, et al. HER-2 overexpression and targeted treatment by trastuzumab in a very old patient with gastric cancer. *J Intern Med* 2006; 260(5): 484-7. [CrossRef]
- Saif MW, Diasio R. Is capecitabine safe in patients with gastrointestinal cancer and dihydropyrimidine dehydrogenase deficiency? *Clin Colorectal Cancer* 2006; 5(5): 359-62. [CrossRef]
- Stubblefield MD, Custodio CM, Kaufmann P, Dickler MN. Small-Fiber Neuropathy Associated with Capecitabine (Xeloda)-induced Hand-foot Syndrome: A Case Report. *J Clin Neuromuscul Dis* 2006; 7(3): 128-32. [CrossRef]
- Vogt T, Coras B, Hafner C, Landhauer M, Reichl A. Antiangiogenic therapy in metastatic prostate carcinoma complicated by cutaneous lupus erythematoses. *Lancet Oncol* 2006; 7(8): 695-7. [CrossRef]
- Saini KS, Attili SV, Saini ML, Batra U, Lakshmaiah KC, Acharya R, et al. Capecitabine induced Hand foot Syndrome. *HIACM* 2007; 8(2): 144-5.
- Tavares-Bello R. Capecitabine-induced hand-foot syndrome and cutaneous hyperpigmentation in an elderly vitiligo patient. *J Eur Acad Dermatol Venereol* 2007; 21(10): 1434-5. [CrossRef]
- Sapp CM, DeSimone P. Palmar-plantar erythrodysesthesia associated with scrotal and penile involvement with capecitabine. *Clin Colorectal Cancer* 2007; 6(5): 382-5. [CrossRef]

35. Lee SD, Kim HJ, Hwang SJ, Kim YJ, Nam SH, Kim BS. Hand-foot syndrome with scleroderma-like change induced by the oral capecitabine: a case report. *Korean J Intern Med* 2007; 22(2): 109-12. [CrossRef]
36. Bosch TM, Meijerman I, Beijnen JH, van Thiel SW, Vlasveld T. Lethal toxicity of uracil/tegafur in the treatment of sigmoid carcinoma. *Ann Oncol* 2007; 18(3): 607-8. [CrossRef]
37. Bianconi M, Jankilevich G, Otero S, Nassif J, Storino C. Successful salvage of a relapsed high risk gestational trophoblastic neoplasia patient using capecitabine. *Gynecol Oncol* 2007; 106(1): 268-71. [CrossRef]
38. Cho HJ, Kim SJ, Kim SY, Han HS, Hong YS, Kim SH, et al. Pathologic complete response after palliative 3rd line chemotherapy with capecitabine alone in metastatic colorectal cancer. *Cancer Chemother Pharmacol* 2009; 63(3): 549-53. [CrossRef]
39. Yucler I, Guzin G. Topical henna for capecitabine induced hand-foot syndrome. *Invest New Drugs* 2008; 26(2): 189-92. [CrossRef]
40. Trindade F, Haro R, Fariña MC, Requena L. Hand-foot syndrome with sclerodactyly-like changes in a patient treated with capecitabine. *Am J Dermatopathol* 2008; 30(2): 172-3. [CrossRef]
41. Vickers MM, Easaw JC. Palmar-plantar hyperpigmentation with capecitabine in adjuvant colon cancer. *J Gastrointest Cancer* 2008; 39(1-4): 141-3. [CrossRef]
42. Surjushe A, Vasani R, Medhekar S, Thakre M, Saple DG. Hand-foot syndrome due to capecitabine. *Indian J Dermatol* 2008; 53(1): 43-4. [CrossRef]
43. Goutos I, Kaniorou-Larai M, Dziewulski P. "Hand-foot" syndrome-an unusual case of plantar pathology presenting to a burns unit. *J Burn Care Res* 2009; 30(3): 529-32. [CrossRef]
44. Endrizzi BT, Lee PK. Management of carcinoma of the skin in solid organ transplant recipients with oral capecitabine. *Dermatol Surg* 2009; 35(10): 1567-72. [CrossRef]
45. Villalon G, Martín JM, Pinazo MI, Caldach L, Alonso V, Jordá E. Focal acral hyperpigmentation in a patient undergoing chemotherapy with capecitabine. *Am J Clin Dermatol* 2009; 10(4): 261-3. [CrossRef]
46. López V, Martín JM, Jordá E, Jordá E. Severe palmar-plantar erythrodysesthesia after treatment with capecitabine. *J Eur Acad Dermatol Venereol* 2010; 24(1): 106. [CrossRef]
47. Wong M, Choo SP, Tan EH. Travel warning with capecitabine. *Ann Oncol* 2009; 20(7): 1281. [CrossRef]
48. Baena-Canada JM, Martínez MJ, García-Olmedo O, Jiménez-Bárceñas R, Muriel-Cueto P. Interaction between capecitabine and brivudin in a patient with breast cancer. *Nat Rev Clin Oncol* 2010; 7(1): 55-8. [CrossRef]
49. Disel U, Gürkut O, Abali H, Kaleağasi H, Mertsoylu H, Ozyilkcan O, et al. Unilateral hand-foot syndrome: an extraordinary side effect of capecitabine. *Cutan Ocul Toxicol* 2010; 29(2): 140-2. [CrossRef]
50. Gafson AR, Goodkin O, Begent R. Observations and hypothesis on an individual patient topically treated for capecitabine-induced Palmar-Plantar syndrome. *BMJ Case Rep* 2010; 2010.
51. Vasudevan B. An unusual case of capecitabine hyperpigmentation: Is hyperpigmentation a part of hand-foot syndrome or a separate entity? *Indian J Pharmacol* 2010; 42(5): 326-8. [CrossRef]
52. Bayraktar S, Garcia-Buitrago MT, Hurley E, Gluck S. Surviving metastatic breast cancer for 18 years: a case report and review of the literature. *Breast J* 2011; 17(5): 521-4. [CrossRef]
53. Gordon VL, Harding GA, Czaykowski P. Capecitabine-induced, nonneutropenic enterocolitis. *J Gastrointest Cancer* 2011; 42(4): 278-81. [CrossRef]
54. Serdar ZA, Gönenç I, Yaşar Ö, Doruk T, Döner N. Hand-Foot Syndrome Accompanied by Severe Oral Lesions during Capecitabine Therapy for Metastatic Colon Carcinoma. *Marmara Medical Journal* 2011; 24: 200-2.
55. Qiao J, Fang H. Hand-foot syndrome related to chemotherapy. *CMAJ*, 2012. 184(15): E818. [CrossRef]
56. Almeida da Cruz L, Hoff PM, Ferrari CL, Riechelmann RS. Unilateral hand-foot syndrome: does it take sides? Case report and literature review. *Clin Colorectal Cancer* 2012; 11(1): 82-4. [CrossRef]
57. Sanghi S, Grewal RS, Brig, Vasudevan B, Nagure A. Capecitabine induced Hand-Foot Syndrome: Report of two cases. *Med J Armed Forces India* 2013; 69(1): 65-7. [CrossRef]
58. Chan HY, Ng CM, Tiu SC, Chan AO, Shek CC. Hypertriglyceridaemia-induced pancreatitis: a contributory role of capecitabine? *Hong Kong Med J* 2012; 18(6): 526-9.
59. Lipshitz J, Astrow AB, Xu Y. A unique and as yet unexplored subset of metastatic colorectal cancer: widespread lymph-node-only recurrence. *J Gastrointest Cancer* 2013; 44(4): 466-71. [CrossRef]
60. Tanaka Y, Oura S, Yoshimasu T, Ohta F, Naito K, Nakamura R, et al. Response of meningeal carcinomatosis from breast cancer to capecitabine monotherapy: a case report. *Case Rep Oncol* 2013; 6(1): 1-5. [CrossRef]
61. Marinelli S, Granito A, Piscaglia F, Renzulli M, Stagni A, Bolondi L. Metronomic capecitabine in patients with hepatocellular carcinoma unresponsive to or ineligible for sorafenib treatment: report of two cases. *Hepat Mon* 2013; 13(9): e11721. [CrossRef]
62. Inokuchi M, Ishikawa S, Furukawa H, Takamura H, Ninomiya I, Kitagawa H, et al., Treatment of capecitabine-induced hand-foot syndrome using a topical retinoid: A case report. *Oncol Lett* 2014; 7(2): 444-8. [CrossRef]
63. Perri F, Muto P, Argenone A, Ionna F, Longo F, Fulciniti F, et al. Induction chemotherapy with docetaxel, cisplatin and capecitabine, followed by combined cetuximab and radiotherapy in patients with locally advanced inoperable squamous cell carcinoma of the head and neck: a phase I-II study. *Oncology* 2013; 84(4): 251-4. [CrossRef]
64. Mishra A, Shrestha PR, Ramanna Rao RV, Kumar A. Nasal involvement in hand and foot syndrome. *Indian J Dermatol* 2013; 58(2): 164. [CrossRef]
65. Ilyas S, Wasif K, Saif MW. Topical henna ameliorated capecitabine-induced hand-foot syndrome. *Cutan Ocul Toxicol* 2014; 33(3): 253-5. [CrossRef]
66. Prakasam PJ, Krishnan DG, Mohanta GP. A Case Report on Capecitabine Induced Hand Foot Syndrome and Mucositis. *Indian Journal of Pharmacy Practice* 2014; 7(4): 47-9.
67. Parikh SA, Markovic SN, Brewer JD. Oral capecitabine to prevent recurrent cutaneous squamous cell carcinoma in a lung transplant recipient. *Int J Dermatol* 2015; 54(9): e358-60 [CrossRef]
68. Elmas OF, Metin MS, Kızılyel O, Aktaş A, Birdal C. [A case of palmoplantar dysesthesia syndrome caused by capecitabine]. *Agri* 2016; 28(1): 54-6.
69. Li Z, Jiang N, Xu Y. The concurrence of subacute cutaneous lupus erythematosus and hand-foot syndrome in a patient undergoing capecitabine chemotherapy. *Australas J Dermatol* 2016; 57(1): e14-6. [CrossRef]
70. Rovere RK, De Lima AS. Forbidden to Drive - a New Chemotherapy Side Effect. *Klin Onkol* 2015; 28(5): 370-2. [CrossRef]
71. Mazza C, Slimano F, Visseaux L, Ordab MA, Botsen D, Grange F, et al. Capecitabine and adermatoglyphia: trouble in border! *J Eur Acad Dermatol Venereol* 2017; 31(6): e283-4. [CrossRef]
72. Chen GY, Chang TW, Chen WC. Exudative hyponychial dermatitis associated with capecitabine and docetaxel combination chemotherapy for metastatic breast carcinoma: report of three cases. *Br J Dermatol* 2003; 148(5): 1071-3. [CrossRef]
73. Uslu G, Karaman G, Uslu M, Şavk E, Şendur N, Meydan N. Kapesitabin Tedavisi Alan Hastada Gelişen El-Ayak Sendromu. *Türkderm* 2006; 40: 105-7.
74. Kara IO, Sahin B, Erkiş M. Palmar-plantar erythrodysesthesia due to docetaxel-capecitabine therapy is treated with vitamin E without dose reduction. *Breast* 2006; 15(3): 414-24. [CrossRef]
75. Tham YL, Hinckley L, Teh BS, Elledge R. Long-term clinical response in leptomeningeal metastases from breast cancer treated with capecitabine monotherapy: a case report. *Clin Breast Cancer* 2006; 7(2): 164-6 [CrossRef].
76. Goyal R, Chalamalasetty SB, Madan K, Paul SB, Arora R, Safaya R, et al. Acral and palmo-plantar hyperpigmentation in a patient with disseminated hepatocellular carcinoma. *Indian J Gastroenterol* 2007; 26(6): 292-3.
77. Shigekawa T, Takeuchi H, Misumi M, Matsuura K, Sano H, Fujiuchi N, et al. Successful treatment of leptomeningeal metastases from breast cancer using the combination of trastuzumab and capecitabine: a case report. *Breast Cancer* 2009; 16(1): 88-92. [CrossRef]
78. Saif MW, Sandoval A. Atypical hand-and-foot syndrome in an African American patient treated with capecitabine with normal DPD activity: is there an ethnic disparity? *Cutan Ocul Toxicol* 2008; 27(4): 311-5. [CrossRef]
79. Karatay E, Akbal E, Koca D, Gönülalan G, Altınbaş M. Kapesitabin tedavisi alan hastada gelişen atipik el ayak sendromu: Olgu sunumu. *Türk Onkoloji Dergisi* 2008; 23(3): 140-1.
80. Shahrokni A, Rajebi MR, Saif MW. Toxicity and efficacy of 5-fluorouracil and capecitabine in a patient with TYMS gene polymorphism: A challenge or a dilemma? *Clin Colorectal Cancer* 2009; 8(4): 231-4. [CrossRef]

81. Mignogna MD, Fortuna G, Falletti J, Leuci S. Capecitabine-induced stomatitis: a likely pathogenetic mechanism of oral lichenoid mucositis. *Eur J Clin Pharmacol* 2009; 65(10): 1057-9. [\[CrossRef\]](#)
82. Baretta Z, Ghiotto C, Marino D, Jirillo A. Aloe-induced hypokalemia in a patient with breast cancer during chemotherapy. *Ann Oncol* 2009; 20(8): 1445-6. [\[CrossRef\]](#)
83. Vrdoljak E, Mise BP, Lukić B, Curić Z, Bosković L, Tica I. Long-lasting control of triple-negative metastatic breast cancer with the novel drug combination ixabepilone and capecitabine--case report. *Onkologije*; 2010; 33(1-2): 53-6. [\[CrossRef\]](#)
84. Yoshida Y, Hoshino S, Shiwaku H, Beppu R, Tanimura S, Tanaka S, et al. Early start of chemotherapy after resection of primary colon cancer with synchronous multiple liver metastases: a case report. *Case Rep Oncol* 2011; 4(2): 250-4. [\[CrossRef\]](#)
85. Hoesly FJ, Baker SG, Gunawardane ND, Cotliar JA. Capecitabine-induced hand-foot syndrome complicated by pseudomonal superinfection resulting in bacterial sepsis and death: case report and review of the literature. *Arch Dermatol* 2011; 147(12): 1418-23. [\[CrossRef\]](#)
86. Akash SS, Bhounsule AS. Oral Capecitabine - Can It Cause The Hand-Foot Syndrome? *Journal of Clinical and Diagnostic Research* 2011; 5(2): 376-8.
87. Ferreira A, Vieira C, Rodrigues A, Pereira D, Rodrigues H, Dávila C, et al. Bevacizumab in the treatment of metastatic breast cancer: three case reports. *Curr Opin Oncol* 2011; 23 Suppl: S11-9. [\[CrossRef\]](#)
88. Richey SL, Ng C, Lim ZD, Jonasch E, Tannir NM. Durable remission of metastatic renal cell carcinoma with gemcitabine and capecitabine after failure of targeted therapy. *J Clin Oncol* 2011; 29(8): e203-5. [\[CrossRef\]](#)
89. Ozkan C, Arslan C, Kilic MK, Erman M, Altundag K. Pituitary Gland Metastasis of Breast Cancer: A Case Report. *International Journal of Hematology and Oncology* 2011; 21:1-4.
90. Al-Ahwal MS. Chemotherapy and fingerprint loss: beyond cosmetic. *Oncologist* 2012; 17(2): 291-3. [\[CrossRef\]](#)
91. Rolski J, Karczarek-Borowska, Smietana A. The possibility of lapatinib treatment for breast cancer patients with central nervous system metastases. Case study and literature review. *Contemp Oncol (Pozn)* 2012; 16(6): 582-5. [\[CrossRef\]](#)
92. Yan S, Jiang X, Yang J, Yan D, Wang YX. Radiotherapy for nasopharyngeal carcinoma and combined capecitabine and nimotuzumab treatment for lung metastases in a liver transplantation recipient: a case experience of sustained complete response. *Cancer Biother Radiopharm* 2012; 27(8): 519-23. [\[CrossRef\]](#)
93. Uleer C, Yazdan-Pourfard J, Holland B, Karl-Friedrich B, Moisisdis-Tesch C, von Minckwitz G. Long-Term Partial Remission with Capecitabine/Trastuzumab in a Patient with Metastatic Breast Cancer Following Progression on Trastuzumab Alone. *Breast Care (Basel)* 2012; 7(1): 45-47. [\[CrossRef\]](#)
94. Vincent A, Lesser G, Brown D, Vern-Gross T, Metheny-Barlow L, Lawrence J, et al. Prolonged regression of metastatic leptomeningeal breast cancer that has failed conventional therapy: a case report and review of the literature. *J Breast Cancer* 2013; 16(1): 122-6. [\[CrossRef\]](#)
95. Lal HS. Hand and foot syndrome secondary to capecitabine. *Indian J Dermatol Venereol Leprol* 2014; 80(5): 427-30. [\[CrossRef\]](#)
96. Yoshida Y, Hoshino S, Aisu N, Naito M, Tanimura S, Sasaki T, et al. Efficacy of XELOX plus Bevacizumab in Brain Metastasis from Rectal Cancer. *Case Rep Oncol* 2014; 7(1): 117-21. [\[CrossRef\]](#)
97. Kigen G, Busakhala N, Njiru E, Chite F, Loehrer P. Palmar-plantar erythrodysesthesia associated with capecitabine chemotherapy: a case report. *Pan Afr Med J* 2015; 21: 228. [\[CrossRef\]](#)
98. Matsuda S, Koketsu H, Hayakawa M, Nagata N. Unilateral Capecitabine-related Hand-foot Syndrome. *Intern Med* 2015; 54(21): 2779. [\[CrossRef\]](#)
99. Chavarri-Guerra Y, Sote-Perez-de-Celis E. Loss of Fingerprints. *N Engl J Med*, 2015. 372(16). [\[CrossRef\]](#)
100. Del Re M, Quaquareni E, Sottotetti F, Michelucci A, Palumbo R, Simi P, et al. Uncommon dihydropyrimidine dehydrogenase mutations and toxicity by fluoropyrimidines: a lethal case with a new variant. *Pharmacogenomics* 2016; 17(1): 5-9. [\[CrossRef\]](#)
101. Takeshita N, Fukunaga T, Kimura M, Sugamoto Y, Tasaki K, Hoshino I, et al. Successful resection of metachronous para-aortic, Virchow lymph node and liver metastatic recurrence of rectal cancer. *World J Gastroenterol* 2015; 21(44): 12722-8. [\[CrossRef\]](#)
102. Lightowers S, Soomal R. Loss of fingerprints secondary to palmo-plantar erythrodysesthesia in a patient on capecitabine chemotherapy. *BMJ* 2015; (35): h6023. [\[CrossRef\]](#)
103. Hashida H, Satake H, Kaihara S. A Complete Response Case in a Patient with Multiple Lung Metastases of Rectal Cancer Treated with Bevacizumab plus XELIRI Therapy. *Case Rep Oncol* 2017; 10(1): 81-5. [\[CrossRef\]](#)
104. Ljubojevic Hadzavdic S, Stulhofer Buzina D, Murtezani I, Skerlev M. Unusual scrotal and penile ulcerations together with palmar-plantar erythrodysesthesia syndrome in a patient with metastatic colon carcinoma treated with capecitabine. *J Eur Acad Dermatol Venereol* 2017; 31(6): e304-6. [\[CrossRef\]](#)
105. Singh B, Tripathy T, Kar BR, Singh S. Involvement of scars in capecitabine induced hand foot syndrome. *Indian J Dermatol Venereol Leprol* 2018; 84(1): 85-7. [\[CrossRef\]](#)
106. Heo YS, Chang HM, Kim TW, Ryu MH, Ahn JH, Kim SB, et al. Hand-foot syndrome in patients treated with capecitabine-containing combination chemotherapy. *J Clin Pharmacol* 2004; 44(10): 1166-72. [\[CrossRef\]](#)
107. Lipworth AD, Robert C, Zhu AX. Hand-foot syndrome (hand-foot skin reaction, palmar-plantar erythrodysesthesia): focus on sorafenib and sunitinib. *Oncology* 2009; 77(5): 257-71. [\[CrossRef\]](#)
108. Yokokawa T, Kawakami K, Mae Y, Sugita K, Watanabe H, Suzuki K, et al. Risk Factors Exacerbating Hand-Foot Skin Reaction Induced by Capecitabine plus Oxaliplatin with or without Bevacizumab Therapy. *Ann Pharmacother* 2015; 49(10): 1120-4. [\[CrossRef\]](#)
109. Naito M, Yamamoto T, Hara S, Shimamoto C, Miwa Y. Hemoglobin Value Is the Most Important Factor in the Development of Hand-Foot Syndrome under the Capecitabine Regimen. *Chemotherapy* 2017; 62(1): 23-9. [\[CrossRef\]](#)
110. Belum VR, Serna-Tamayo C, Wu S, Lacouture ME. Incidence and risk of hand-foot skin reaction with cabozantinib, a novel multikinase inhibitor: a meta-analysis. *Clin Exp Dermatol* 2016; 41(1): 8-15. [\[CrossRef\]](#)
111. Marse H, Van Cutsem E, Grothey A, Valverde S. Management of adverse events and other practical considerations in patients receiving capecitabine (Xeloda). *Eur J Oncol Nurs* 2004; 8 Suppl 1: S16-30. [\[CrossRef\]](#)
112. Hoffmann-La Roche Limited, XELODA® Product Monograph. Mississauga, Ontario, 31 July 2002.
113. Macedo LT, Lima JP, dos Santos LV, Sasse AD. Prevention strategies for chemotherapy-induced hand-foot syndrome: a systematic review and meta-analysis of prospective randomised trials. *Support Care Cancer* 2014; 22(6): 1585-93. [\[CrossRef\]](#)
114. Zhou Y, Peng L, Li Y, Chen L. Prophylactic pyridoxine was not able to reduce the incidence of capecitabine-induced hand-foot syndrome: A meta-analysis. *Biomed Rep* 2013; 1(6): 873-8. [\[CrossRef\]](#)
115. Mortimer JE, Lauman MK, Tan B, Dempsey CL, Shillington AC, Hutchins KS. Pyridoxine treatment and prevention of hand-and-foot syndrome in patients receiving capecitabine. *J Oncol Pharm Pract* 2003; 9: 161-6. [\[CrossRef\]](#)
116. Jo SJ, Shin H, Jo S, Kwon O, Myung SK. Prophylactic and therapeutic efficacy of pyridoxine supplements in the management of hand-foot syndrome during chemotherapy: a meta-analysis. *Clin Exp Dermatol* 2015; 40(3): 260-70. [\[CrossRef\]](#)
117. Lassere Y, Hoff P. Management of hand-foot syndrome in patients treated with capecitabine (Xeloda). *Eur J Oncol Nurs* 2004; 8 Suppl 1: S31-40. [\[CrossRef\]](#)
118. Brown J, Burck K, Black D, Collins C. Treatment of cytarabine acral erythema with corticosteroids. *J Am Acad Dermatol* 1991; 24(6 Pt 1): 1023-5. [\[CrossRef\]](#)
119. Gomez P, Lacouture ME. Clinical presentation and management of hand-foot skin reaction associated with sorafenib in combination with cytotoxic chemotherapy: experience in breast cancer. *Oncologist* 2011; 16(11): 1508-19. [\[CrossRef\]](#)
120. Serrano Fernandez MP, Gutiérrez Vilella MJ, Pérez Martín-Palanco A, Vanaclocha Sebastián F, Cabezón Gutiérrez L. [Palmar-plantar erythrodysesthesia syndrome local cold prevention]. *Rev Enferm* 2011; 34(9): 42-6.